

A new “VBH TRINITY” mini plate for Mandibular osteosynthesis: an in vivo pilot study

¹Dr. Venkatesh Balaji Hange , Postgraduate Student, Department of Oral And Maxillofacial Surgery, K. D. Dental College & Hospital, Mathura, Uttar Pradesh.

²Dr.Shishir Mohan Devki, Head of Department, Department of Oral and Maxillofacial Surgery, K.D. Dental College & Hospital, Mathura, Uttar Pradesh.

³Dr. Hasti Kankariya, Professor, Department of Oral And Maxillofacial Surgery, K. D. Dental College & Hospital, Mathura, Uttar Pradesh.

⁴Dr.Shrey Srivastava, Postgraduate Student, Department of Oral And Maxillofacial Surgery, K. D. Dental College & Hospital, Mathura, Uttar Pradesh.

Corresponding Author: Dr. Venkatesh Balaji Hange, Postgraduate Student, Department of Oral and Maxillofacial Surgery, K. D. Dental College & Hospital, Mathura, Uttar Pradesh.

Type of Publication: Case Report

Conflicts of Interest: Nil

Abstract

Background: The possible drawbacks of 3D mini plate can be unnecessary implant material & in cases of oblique fractures passing mental foramen. The aim of our study is therefore to create an alternative to 3D mini plates that will overcome the limitations of the 3D mini plate without compromising the stability of the plate.

Methods: This in-vivo study was done on patients with mandibular fractures at the department of Oral and Maxillofacial Surgery, K.D Dental College and Hospital, Mathura. A total of 20 patients were randomized and divided into the two groups ,Group A & B.The patients were evaluated preoperatively, intraoperative and postoperatively for Plate adaptation / fixation interval ,Hardware failure ,Rigidity & tensile strength of the implant material ,Neurosensory changes .

Result: The mean age of 10 patients in Group A was 25.2 years. The mean age of 10 patients in Group B was 25.6 years. Both group A & B comprised of males i.e. 10 males in each group.20 patients underwent treatment for mandibular fracture , most common site of fracture in both

group A & B was parasymphysis (50%-60%) .Aetiology of fracture was RTA in 70% of the subjects , assaults in 20% of the subjects and self fall in 10% of the subjects among group A & group B. Difficulty in adaptation of plate during surgical procedure of mandibular fracture fixation was found in 20% of the subjects of the group B ,while same was not recorded in any of the Group A cases. Hardware failure was found among 30% cases of Group B where as 10% cases among Group A. tensile strength of the Group A is 14% higher than the Group B.

Conclusion: Trinity mini plate (Group A) ,could be used successfully for fixation of mandible fractures. Trinity mini plate seems to be an easy alternative to conventional miniplate.

Keywords: 3D mini plate, Mandibular fracture, mini plate osteosynthesis, Nerve paresthesia, Biomechanical study.

Introduction

Mandibular fractures are common facial injuries accounting for 36 to 59% of all maxillofacial fractures and their treatment is one of the most frequent forms of therapy provided by maxillofacial surgeons.(1) The

management of maxillofacial trauma has evolved greatly over the centuries from supportive bandages, splints, circummandibular wiring, extra oral pins, and semi-rigid fixation with trans-osseous wiring to rigid fixation with compression plates and 2 more lately back to semi-rigid fixation with miniplates.(2) In the numerous investigations carried out by Huelke and Hodgson ,they found that the bone fractures at sites of tensile strain, as resistance to compressive forces is greater.Anterior forces applied to the symphysis menti over one mental foramen or the mandibular body created pressure over opposite molars on the condylar necks and lingual plates .(3)

Varying types of mini plates are developed over last few decades, to provide stable fixation for mandibular fractures.

Internal fixation of mandibular fractures with mini plates (in conformity with the tension band principle) was first introduced by Michelet in 1973 and was later modified by Champy et al. The lag screw technique in maxillofacial surgery was first advocated by Brons and Boering in 1970 and was later reintroduced by Niederdellmann et al.(4) Farmand (1996) introduced the concept of 3-D mini plates. They derive their stability and mechanical properties because of their specialized quadrangular shape, which is dependent on the principle of a quadrangular shape being a geometrically more stable design.The possible drawbacks of this device can be unnecessary implant material due to the additional vertical bars integrated to counteract torsional forces, In cases of oblique fractures, the overall bulk of the plate may require sufficient exposure of the surgical site and fracture of the vertical strut, which, in turn, could compromise the 3-D stability of the plate. (5) The aim of our study is therefore to create an alternative to 3D mini plates that will overcome the limitations of the 3D mini plate without compromising the stability of the plate.

Material & Methods

This in-vivo study was done on patients with mandibular fractures at the department of Oral and Maxillofacial Surgery from May 2019 to January 2020, at K.D Dental College and Hospital, Mathura. Ethical clearance for the study was obtained from the Institutional review board , K.D. Dental College & Hospital ,Mathura,U.P.

Informed consent was taken from all the patients prior to surgery.

Patients were randomly selected as per inclusion and exclusion criteria, regardless of gender, requiring open reduction and internal fixation of mandibular fracture with or without other associated fractures of facial skeleton. Selection criteria included non-comminuted, non-infected mandibular fracture with associated facial fractures.,single non-comminuted fracture of the mandible requiring open reduction with internal fixation for treatment ,subject willingness ,dentulous patients.

However, patients with systemic bone disease like osteoporosis, osteopetrosis, edentulous mandible, comminuted and infected mandibular fractures , .Patients with systemic disease contraindicating general anesthesia ,Patients with history of uncontrolled diabetes mellitus, prolonged steroid therapy, compromised immunity were excluded from the study.

A total of 20 patients were randomized and divided into the following two groups:

Group I: (10 patients) - Newly designed “Trinity” titanium miniplate with 6 holes of 2.0 mm diameter and 1 mm thickness used for fixation of mandibular fracture.(Fig.3-7)

Group II: (10 patients) - Standard 4-hole with gap stainless steel 2.0 mm diameter holes and 1 mm thickness miniplate used for fixation of mandibular fracture.(Fig.8-12)

Full history was registered, patients were clinically assessed and explained in a language which they fully understood about the treatment, its risks and the follow-up duration involved in the study. Under general anesthesia, patients who meet the inclusion criteria were scheduled for open reduction and internal fixation. Routine blood tests (required for pre-anesthetic assessment), radiological investigations (OPG / PA view Mandible / Chest X-ray PA view), ECGs were performed prior to surgery.

Inclusion Criteria

1. Non-comminuted, non-infected mandibular fracture with associated facial fractures.
2. Single non-comminuted fracture of the mandible requiring open reduction with internal fixation for treatment except mandibular coronoid fracture
3. Subject willingness
4. Dentulous patients.

Exclusion Criteria

1. Malunited fracture
2. Infected fracture
3. Mandibular coronoid fracture
4. Fracture in pediatric patients.
5. Edentulous patients.
6. Uncooperative patient
7. Patients with systemic disease contraindicating general anesthesia.
8. Patients with history of uncontrolled diabetes mellitus, prolonged steroid therapy, compromised immunity and associated bone pathology.

Surgical Procedure: Mandibular fracture was exposed through either introral vestibular incision or extra oral incision in case of extra oral laceration / as per access requirement. After fracture site exposure, mandible is reduced to its anatomical position correctly.

Once occlusion was achieved the fractured segments were fixed using. Newly designed TRINITY mini plate or

Conventional stainless steel 4 hole with gap mini plate. Diagonally opposite screws were placed first, followed by the placement of the remaining screws. Adequacy of fixation and occlusion were rechecked after placement of the respective mini plate .Intraoral surgical site was closed with 3-0 silk and skin incision was closed with 3-0 silk suture/ prolene 4-0.

The patients were evaluated preoperatively, intraoperatively and postoperatively for Plate adaptation / fixation interval ,Hardware failure ,Rigidity & tensile strength of the implant material ,Neurosensory changes . Postoperative clinical evaluation was done at the 1st week, 15th day, 3rd month and 4th month respectively . Preoperatively radiographs were taken as deemed necessary by the surgeon and similar radiographs were taken postoperatively to check the adequacy of reduction and fixation.

Results

The mean age of 10 patients in Group A was 25.2 years with maximum age of patient 40 years & minimum being 18 years .The mean age of 10 patients in Group B was 25.6 years with maximum age of patient 36 years & minimum being 20 years. Both group A & B comprised of males i.e. 10 males in each group.

Table 1: Fracture Site Distribution among Study Subjects

	Group A		Group B	
	N	%	N	%
Fracture parasymphysis	5	50	6	60
Fracture Symphysis	2	20	1	10
Fracture Body	2	20	1	10
Fracture Angle	1	10	2	20

The Study shows (Table 1) that in all, 20 patients underwent treatment for mandibular fracture, most common site of fracture in both group A & B was parasymphysis (50%-60%).

Aetiology of fracture (Fig. 1) was RTA in 70% of the subjects, assaults in 20% of the subjects and self fall in 10% of the subjects among group A & group B.

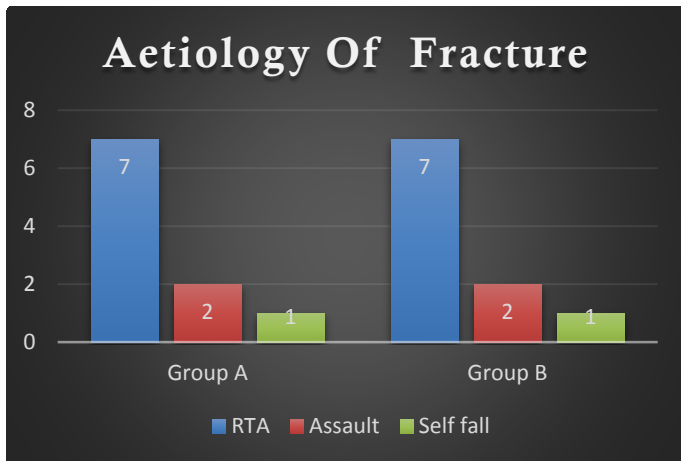


Figure 1: Aetiology of fracture among Group A & Group B

Variables	Group A		Group B		Chi square	P value
	N	%	N	%		
Surgical approach						
Intra-oral	4	40	6	60	0.8	0.37
Extra-oral	6	60	4	40		

Table 2: Surgical approach for fracture fixation among Group A & Group B.

In Group A ,intra-oral & extra oral surgical approach was adopted in 40% & 60% of the subjects respectively while in Group B,intra-oral & extra oral surgical approach was adopted in 40% & 60% of the subjects respectively (Table 2) with statistically insignificant difference when compared using chi square test between two groups.

Table 3: Plate adaptation / fixation interval among Group A & Group B

Plate adaptation / fixation interval	Mean	Standard deviation	Chi Square	P value
Group A	21.30	4.38	1.58	0.13
Group B	24.20	3.82		

Difficulty in adaptation of plate during surgical procedure of mandibular fracture fixation was found in 20% of the subjects of the group B (Table 3) ,while same was not recorded in any of the Group A cases when hardware complication was compared among Group A & Group B using Fischer exact test , it was found to be statistically insignificant.

Hardware complications	Group A		Group B		Fischer exact	P value
	N	%	N	%		
None	10	100	8	80	1.27	0.474
Difficulty in plate adaptation	0	0	2	20		

Table 4: Comparison of Hardware failure among Group A & Group B

Variables	Group A		Group B		Fischer exact	P value
	N	%	N	%		
1 st week	0	0	1	10	0.582	0.16
15 days	0	0	0	0		
1 month	0	0	0	0		
3 month	1	10	2	20		

Table 5: Comparison of Hardware failure among Group A & Group B at different time intervals

(Table 4&5) showing the comparison of hardware failure among group A & group B , at 1st week , 15 days , 1st month & 3rd month post-operatively. Hardware failure was found among 30% cases of Group B where as 10% cases

among Group A. when hardware failure was compared among Group A & Group B using fisher exact test.

Tensile Strength Test polymethylmethacrylate (PMMA) replica of mandibles, Trinity mini plate supplied by S.K. surgicals (Fig 14 a)& conventional 4 hole with gap ,2 hole with gap s.s. mini plate by Orthomax surgical (Fig.14b), osteofixation systems were used as regards the parasymphysis region for tensile strength ,there were significant differences between these two osteofixation system. The tensile strength measurement (Table 6) of Trinity mini plate ,was 649 N whereas tensile strength measurement of conventional Champy’s S.S. mini plate were 565 N , when the osteofixation plate were subjected to a tensile force with a constant speed of 5 mm/min until fracture occurred.(according to ASTM D 4501 Guideline) During testing the applied force was recorded by the load cell of the test machine.

Table 6: Tensile load results

Test plate system	Test results ,N
Conventional s.s. mini plate	565 N
Trinity titanium mini plate	649 N

As a result, we can conclude that the tensile strength of the trinity mini plate is 14 per cent higher than the conventional stainless steel mini plate system. (Fig.2)The trinity mini plate system is therefore more rigid than the conventional stainless steel mini plates.

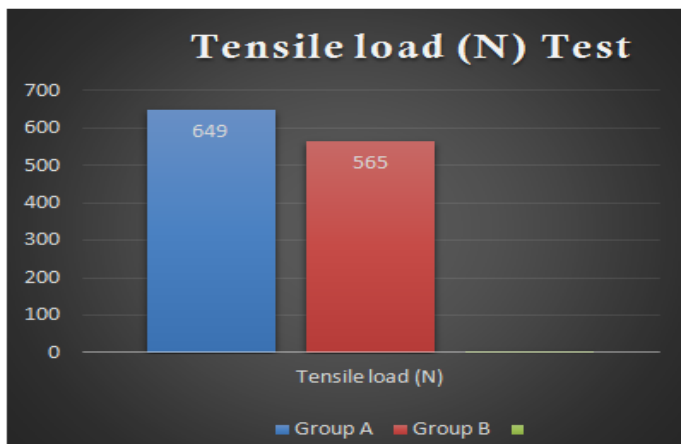


Figure 2: Comparison of Tensile Load (N) Test among Group A (Trinity min plate) & Group B (Conventional s.s. mini plate)

Photographs of Group-A Patient

Right Subcondylar Fracture & Left Parasymphysis Fracture Fixation Using Trinity Mini Plate For Parasymphysis Fracture & Conventional Mini Plate At Condylar Fracture

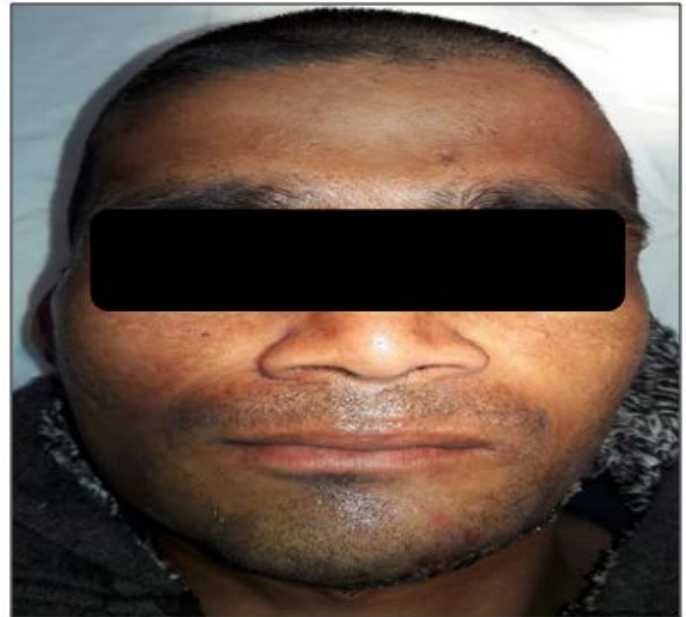

Fig3: Preoperative Front View

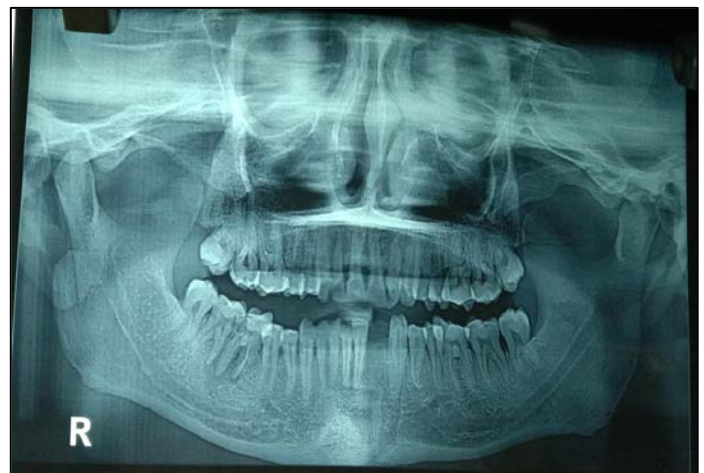

Fig.4: pre operative O.P.G. showing right subcondylar & left parasymphysis fracture

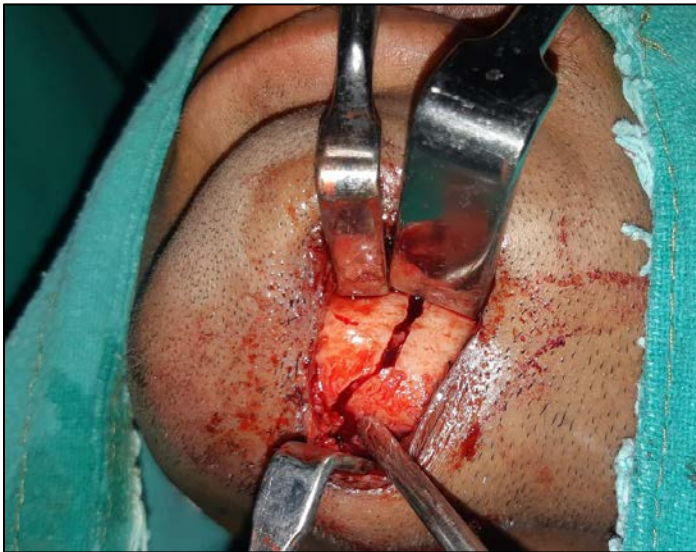

Fig.5: Fracture site exposed using extraoral incision

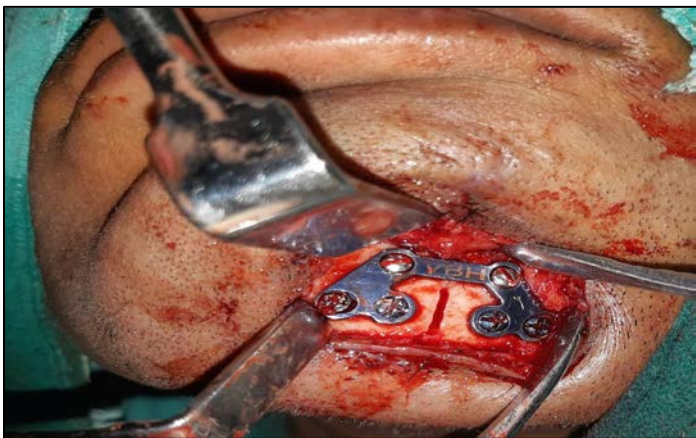


Fig. 6: Fixation using Trinity titanium miniplate

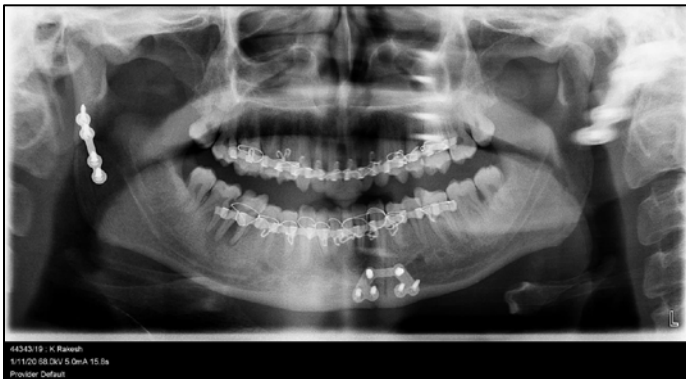

Fig. 7: Post Operative Radio-graph

Photographs of Group-B Patient

Left Mandibular Parasymphysis Fracture, & Right Angle Fracture Fixation with Conventional S.S. Mini Plates Using Intraoral & Submandibular Incision

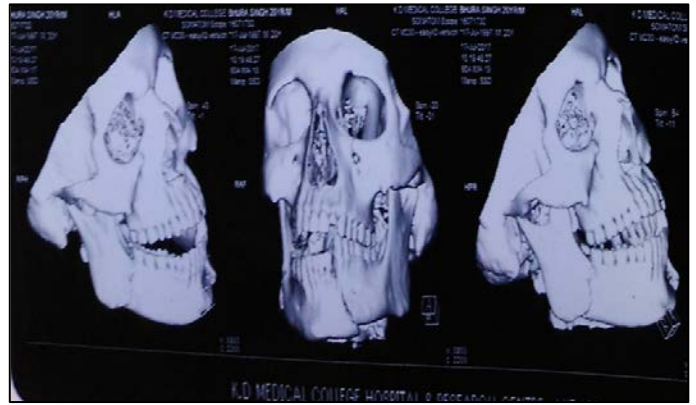

Fig. 8:Pre-operative 3D reconstruction CT Scan showing right angle & left parasymphysis fracture.

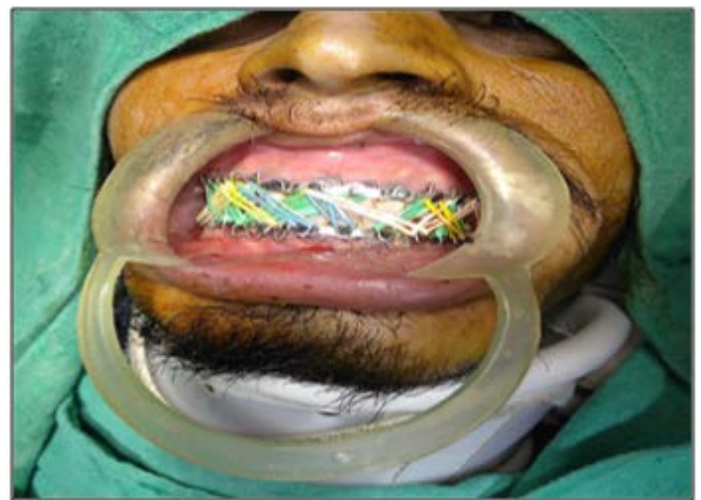

Fig.9: showing closed reduction & IMF using elastics.

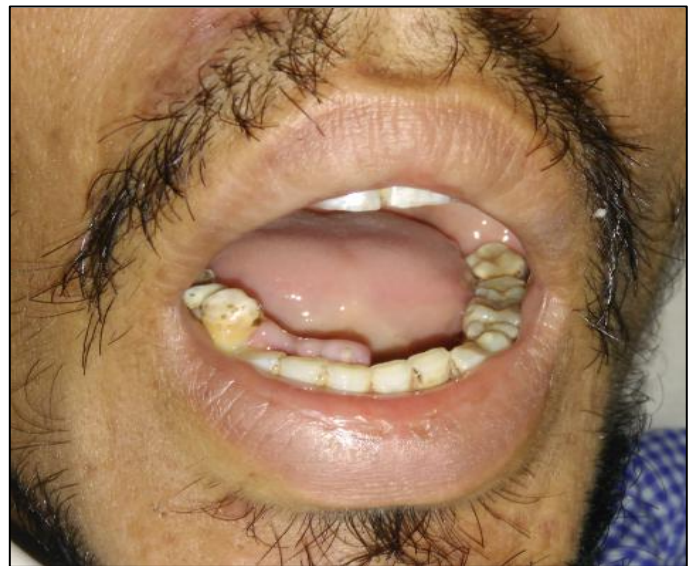

Fig.10: showing pre-operative occlusion with severe lingual splaying.

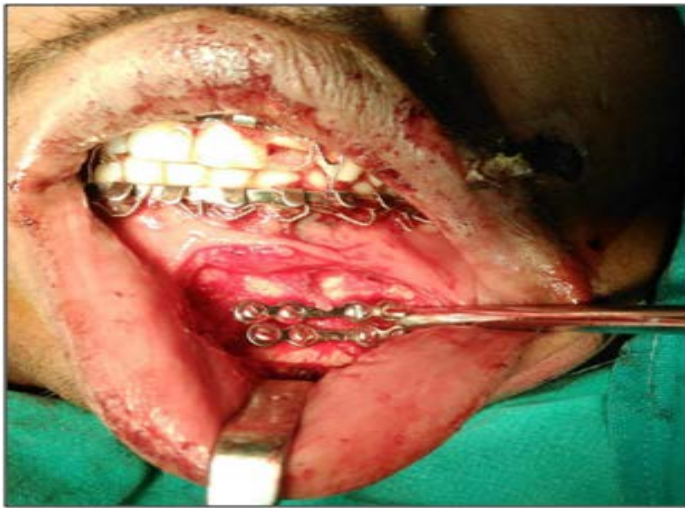

Fig.11: fixation at parasymphysis fracture using two 4 hole with gap S.S. mini plates.

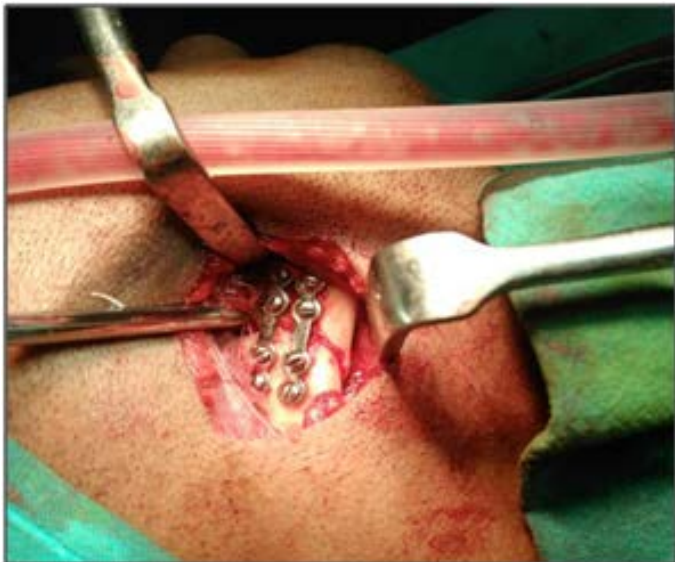

Fig.12 fixation at angle fracture using two 4 hole with gap S.S. mini plates.



Fig. 13: Newly designed TRINITY mini plate

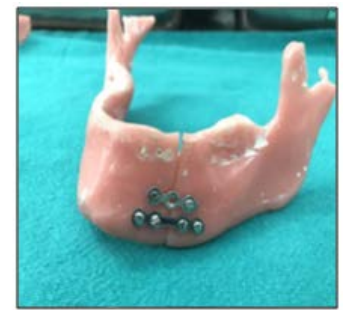
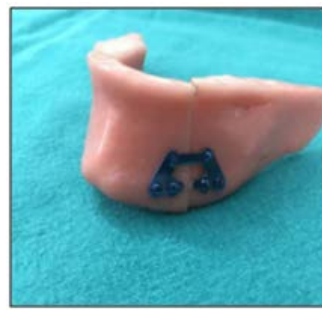
Fig.14 a): showing acrylic mandible replica split fracture line passing through mental foramen fixation done using Trinity mini plate. b) showing acrylic mandible replica split fracture line passing through mental foramen fixation done using conventional 4 hole with gap & 3 hole without gap s.s. mini plate.

Discussion

Basic principles of mandibular fracture treatment include reduction, fixation, immobilization, and supportive therapies. The first and most important aspect of surgical correction is to reduce the fracture properly and place the individual segments of fracture into proper relationship with each other.(6)

In 1973, Michelet et al described the treatment of mandibular fractures using small, easily bendable, non compression mini plates placed transorally and anchored with 2-mm monocortical screws. Subsequently, Champy et.al. extensively researched and improved the technique, designing miniplates with a high level of elasticity and malleability.(7) Mostafa Farmand (1993) introduced new 3D plating system. The 3D plate design is based upon the quadrangle concept as a geometrically stable support configuration. Because 3D stability is achieved by the geometric shape that forms a cuboid, compared with standard miniplates and reconstruction plates, the thickness of these plates is reduced to 1 mm.(8) The main disadvantage of the 3-D plate system is that precise adaptation to the underlying bone, interference with the perfusion of bone underlying the plate.

(9)Titanium has become the biomaterial of choice for Bone fixation systems with plates and metallic screws,since it meets the requirements of resistance, adaptability and biocompatibility.Biomechanically, titanium has a high tensile strength (Weber et al., 1990) and a low modulus of elasticity that allows good contouring to the osseous surface of the facial skeleton (Lemond and Lucas,1986 Marsh, 1989).(10)Titanium was first used in 1940's and was shown to be not only biocompatible but had a tendency for osseointegration and had excellent corrosion resistance. It also has excellent ductility and tensile strengths and totally non-toxic .(11)Champy et al.(1976)described that in the anterior part of the mandible, in front of first premolar, there are mainly moments of torsion. One plate is sufficient proximal the first premolar. Two miniature plates should be separated by 4-5 mm in front of the first premolar to neutralize the moments of torsion.De Oliveira KP et al.conducted a research using 3D models which proved that when loads are applied to chewing points in the posterior region of the mandible where the molar teeth are located, the greatest intensity of torque forces is found in the region of the symphysis.(8)3D miniplate system is difficult to adapt and difficult to use in cases of fractures involving the mental nerve.a 3D plate has to be bent in 3 dimensions, whereas a conventional plate has to be bent only in 2 dimensions, so a 3D plate is much more difficult to perfectly adapt than a conventional plate.(12) The probable limitations of this system may be excessive implant material due to the extra vertical bars incorporated for counteracting the torsional forces &in cases where the fracture line passing through the mental foramina region. overall bulk of plate in cases of oblique fractures and it may require sufficient exposure of surgical site and fracturing of vertical strut, which in turn might compromise 3-D stability of plate. (13,14)As per the above described limitations & disadvantages of 3D

mini plate, we propose a new design of mini plate (Fig.14) as new alternative solution in the open reduction of parasymphysis fracture where mental foramen lies close to the fracture line by making a new design of mini plate.

Conclusion

Our experience in using titanium Trinity mini plate and stainless steel mini plates was based on observations drawn from 20 patients , leading us to variety of conclusions .The groups were comparable to each other in majority of aspects like age , sex ,aetiology, fracture site,biomechanical properties and displacement. Trinity mini plate offers an advantage over stainless steel mini plate of reduced operative time. Both plating system were easy to use , however at curved bony contour of symphseal region , stainless steel plate encountered difficulty in adaptation. Hence we recommended titanium Trinity mini plate due to its superior malleable property.We conducted biomechanical study for tensile strength on Trinity mini plating system and champy's plating system. The result of this study showed that Trinity mini plate is superior than stainless steel plate .Trinity mini plate is 14 % more rigid than the conventional stainless steel plate.The complications, such as hardware failure was seen in 3 patients of stainless steel plate group where as only one patient of titanium Trinity mini plate.Hence we can conclude that titanium Trinity mini plate shows less incidence of post-operative infection .Another complication evaluated in the study were post operative paresthesia. 3 patients of stainless steel plate group developed post operative paraesthesia where as none in Trinity mini plate group. Proving that Trinity mini plate causes less incidence of post operative paraesthesia. So we can say that Trinity mini plate can be used safely in fractures where fracture line passes through mental foramen.Post operative Inter-fragmentary gap between fractured segment is rare inTrinity mini plate group when

comparing with stainless steel plate group. Depending upon requirement of aesthetics or presence of extra oral laceration, amount of exposure both extra-oral & intra-oral approach can be used with ease, for fixation of trinity mini plate. Though our interest of study focused on parasymphysis region of mandible, it is equally effective in body as well as angle region of mandible as per result obtained through our study. (Fig.13) thus Trinity mini plate becomes a new alternative for osteosynthesis of mandibular fractures. All patients in present study appreciated early recovery of normal jaw function, primary healing and good union at fracture. The results we obtained suggested that Titanium Trinity plates could be used successfully for fixation of mandible fractures. The geometrically closed horse shoe shaped design of the plates results in the reduction of material, superior stability; minimize the disturbance to vascular supply easy adaptation and thereby reducing the operating time with fewer complications. To conclude, Trinity mini plate seems to be an easy alternative to conventional miniplates. Limits to our study could be considered as the small sample size and the limited follow up. It is hence recommended to have a multi centre study with large number of patients and correlation among these studies to authenticate our claims.

References

1. Walid A. Ghanem, Khaled A. Elhayes, Khalid Saad, The management of unstable oblique infected mandibular fractures with a 2.3 mm mandibular osteosynthesis reconstruction bone plate, Journal of Cranio-Maxillo-Facial Surgery 39 (2011) 600-605
2. Mohammad Ali R Patel, Mohammad Azharuddin Saidkhan Rathod, Mohammed Haneef, Comparison of 2D vs 3D miniplates in the management of anterior mandibular fractures – a comparative study, RGUHS Med Sciences, April 2016, Vol. - 6, Issue-2, 66-71.
3. Denny George, V.Suresh, R.Sathya Narayanan, V.Yuvaraj et.al., A Comparative Study Between Titanium Mini Plates And 3 Dimensional Titanium Plates With Locking Screws Using Bite Force Evaluation For Management Of Anterior Mandibular Fractures, Journal of scientific dentistry, 6(2), 2016, 7-17.
4. Wusiman P et al., Three-dimensional versus standard miniplate, lag screws versus miniplates, locking plate versus non-locking miniplates: Management of mandibular fractures, a systematic review and meta-analysis, Journal of Dental Sciences, <https://doi.org/10.1016/j.jds.2018.04.004>
5. Vivek GK, Shetty A, Vaibhav N, Imran M. A comparative study of single 3-D titanium plate versus conventional Champy's 2 miniplate fixation in the management of mandibular anterior fracture: A prospective clinical study. J Adv Clin Res Insights 2016;3:194-199.
6. Udupikrishna Joshi, Manju Kurakar, Comparison of Stability of Fracture Segments in Mandible Fracture Treated with Different Designs of Mini-Plates Using FEM Analysis, J. Maxillofac. Oral Surg. (July–Sept 2014) 13(3):310–319.
7. Atson Carlos de Souza Fernandes, Marcelle A. Rossi et.al., Lateral Cortical Bone Thickness of Human Mandibles in Region of Mental Foramen, J Oral Maxillofac Surg 68:2980-2985, 2010.
8. Siddiqui FI, Naphade MV, Naphade UM, Adwani DG, Shroff PR, Anwar SS. Management Of Anterior Mandibular Fractures Using Two Different Fixation Methods. Arch CranOroFac Sc 2016;4(2):4-9
9. Yadav S et al., 3-D locking titanium miniplates in management of mandibular fracture: A prospective clinical study, J Dent Specialities. 2015;3(1):64-67.

10. Julio Acero, Javier Calderon et.al. , The behaviour of titanium as a biomaterial: microscopy study of plates and surrounding tissues in facial osteosynthesis ,Journal of Cranio-Maxillofacial Surgery (1999) 27, 117- 123.
11. Deepak S, Manjula S ,Comparison of Titanium bone plates and screws vs. stainless steel bone plates and screws in the management of mandibular fractures –A long term clinical study ,Int. Journal of Clinical Dental Science ,august, 2011 , 2(3) ,38-44.
12. Mohit Agarwal , Balram Meena , D. K. Gupta ,Anjali Dave Tiwari , Sunil Kumar Jakhar ,A Prospective Randomized Clinical Trial Comparing 3D and Standard Miniplates in Treatment of Mandibular Symphysis and Parasymphysis Fractures ,J. Maxillofac. Oral Surg. (Apr–June 2014) 13(2):79–83.
13. Vivek GK, Shetty A, Vaibhav N, Imran M. A comparative study of single 3-D titanium plate versus conventional Champy's 2 miniplate fixation in the management of mandibular anterior fracture: A prospective clinical study. J Adv Clin Res Insights 2016;3:194-199.
14. Dr.B.Pavan Kumar, Dr. Jeevan Kumar, Dr.A.P.Mohan, Dr.V.Venkatesh & Dr.H.Rahul Kumar ,A Comparative Study Of Three Dimensional Stainless Steel Plate Versus Stainless Steel Miniplate In The Management Of Mandibular Parasymphysis Fracture ,J.Bio.Innov 1(2), pp: 19-32, 2012 .
15. Dr. Venkatesh Balaji Hange,Dr. Shrey Srivastava,A New "Trinity" Mini Plate For Mandibular Osteosynthesis : An In Vitro Study ,Volume-9,Issue-1 , January-2020 |,PRINT ISSN No. 2277 - 8179 , DOI : 10.36106/ijsr.

How to citation this article: Dr. Venkatesh Balaji Hange, Dr. Shishir Mohan Devki, Dr. Hasti Kankariya, Dr. Shrey Srivastava,“A new “VBH TRINITY” mini plate for Mandibular osteosynthesis: an in vivo pilot study”, IJMACR- March - April - 2020, Vol – 3, Issue -2, P. No. 233 – 242.

Copyright: © 2020, Dr. Venkatesh Balaji Hange, et al. This is an open access journal and article distributed under the terms of the creative commons attribution noncommercial License 4.0. Which allows others to remix, tweak, and build upon the work non-commercially, as long as appropriate credit is given and the new creations are licensed under the identical terms.
