

## **Myocarditis and Cardiogenic Shock Associated with Plasmodium Vivax Malaria: A Rare Case Report**

<sup>1</sup>Dr. Gaurav Y. Lakhani, 3<sup>rd</sup> year Post Graduate Resident, Department of Internal Medicine, Government Medical College, Surat, Gujarat.

<sup>1</sup>Dr. Pooja S. Zanzari, 3<sup>rd</sup> year Post Graduate Resident, Department of Internal Medicine, Government Medical College, Surat, Gujarat.

<sup>1</sup>Dr. Priyanka R. Patel, 3<sup>rd</sup> year Post Graduate Resident, Department of Internal Medicine, Government Medical College, Surat, Gujarat.

<sup>2</sup>Dr. Anuj V. Mansata, Ph.D. Research Scholar, Gujarat University, Ahmedabad, Gujarat.

**Corresponding Author:** Dr. Gaurav Y. Lakhani, 3<sup>rd</sup> year Post Graduate Resident, Department of Internal Medicine, Government Medical College, Surat, Gujarat.

**Type of Publication:** Case Report

**Conflicts of Interest:** Nil

### **Abstract**

Malaria is one of the most common parasitic infection in South-East Asia. Complications arising in *P. falciparum* malaria are well documented in world literature but Myocarditis and Cardiogenic shock in *P. vivax* infection is very rare complication. We report a case of these complications in a teenage boy diagnosed with *P.vivax* malaria based on peripheral smear findings. During the course of treatment of Malaria, he developed respiratory distress, and was intubated and mechanically ventilated as well as administered inotropes due to cardiogenic shock secondary to myocarditis.

**Keywords:** Plasmodium vivax, Plasmodium falciparum, Malaria, Myocarditis, Cardiogenic shock, Cerebral Malaria.

### **Introduction**

According to WHO, Malaria is considered to be endemic in South Asian countries, Africa as well as in South American nations. In India, malaria is one of the major public health problem<sup>1</sup> and requires particular attention during health policy formation every year. Out of the four species of malarial parasites (*P. falciparum*, *P. malariae*, *P.*

*ovale* and *P.vivax*), *Plasmodium falciparum* is considered to be most virulent species affecting the humans. Children below 5 years of age and pregnant women are more susceptible to malaria and it may be complicated by involvement of other important organs/tissues like brain (Cerebral Malaria)<sup>2</sup>, heart (Myocarditis, bundle branch block, cardiomyopathy and pericardial effusion), eyes(Retinal Haemorrhage), blood (severe anaemia, metabolic acidosis, jaundice) and lungs (Pulmonary oedema, respiratory distress).<sup>3</sup>

We report here a case of teenage boy having *P. vivax* malaria with atypical complication of Myocarditis and cardiogenic shock.

### **Case Report**

A 15 year old boy with no prior medical history of any systemic diseases presented with complaint of fever with chills since last 4 days along with nausea and vomiting since 2 days. No significant past or family history was recorded during examination. Initial examination of vitals revealed that the patient was afebrile with heart rate 114/minute and blood pressure was 82/60 mm Hg. Bilateral coarse crackles with decreased breath sounds at

left base of lung was observed on examination. No other abnormality was detected during initial examination.

Initial investigations were carried out soon after the examination was completed and the findings are mentioned in Table 1.

Table 1: Investigations and their findings.

Sr. No.	Parameter / Investigation	Findings
1	Haemoglobin	10.1 g / dl
2	Hematocrit	32
3	Total count	7700 / cu. mm.
4	Platelets count	49,000 / cu. mm.
5	Peripheral Smear	Rings, Schizonts and Trophozoites of plasmodium vivax malaria
6	Serum Creatinine	0.9 mg / dl
7	Serum Sodium	132 meq / l
8	Serum Potassium	3.3 meq / l

On the next day of admission to the ward, the condition of patient started deteriorating with respiratory rate 40 / minute, oxygen saturation was 90% on room air with raised jugular venous pressure and hypotension. Electrocardiograph (ECG) showed ST-T wave changes in lateral leads and arterial blood gas analysis (ABGA) revealed respiratory alkalosis. Patient was immediately shifted to Intensive Care Unit (ICU) and was intubated and mechanically ventilated.

Chest radiograph revealed findings suggestive of pulmonary oedema. 2D-ECHO showed dilated left Atrium and dilated left Ventricle along with severe generalised left ventricular hypokinesia with moderate Mitral regurgitation and left ventricular ejection fraction at 15%. (Figure 2)

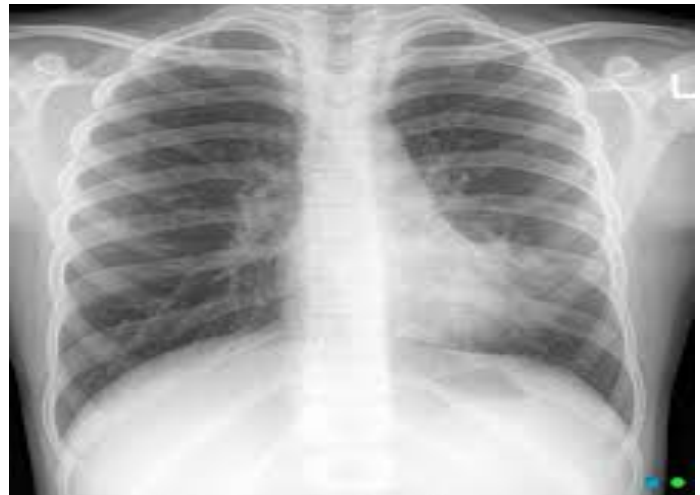

Figure 1: Chest radiograph on day 1 showing infiltrates in left lower zone.

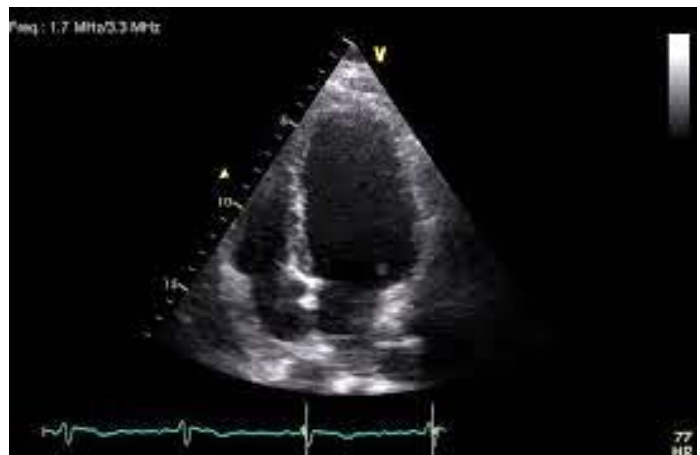

Figure 2: 2D-ECHO of patient on second day of admission.

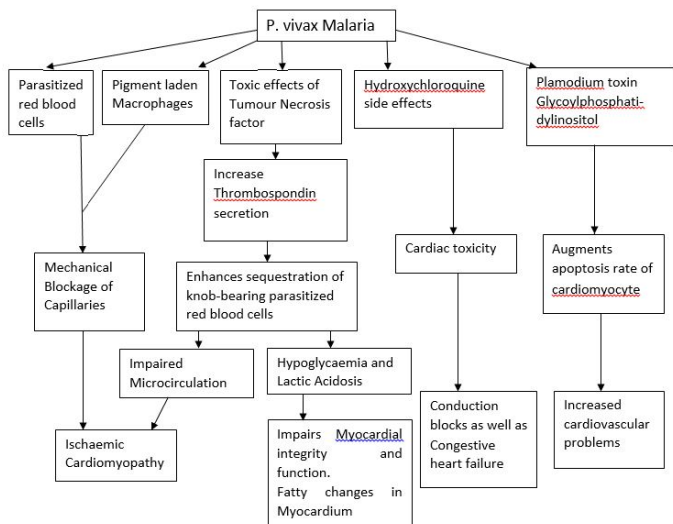
The i.v. fluids were immediately discontinued and patient was administered inotropes, dopamine, dobutamine along with diuretic furosemide. After 48 hours, patient's ventilator requirement showed gradual improvement. After 2 weeks, 2D-ECHO was done again and it showed normal ejection fraction. Peripheral smear on 15<sup>th</sup> day showed negative malarial parasite report. Patient was subsequently discharged and was advised to rest for 1 week.

**Discussion**

Out of the total malaria cases reported, P. vivax malaria accounts for almost 50% of total cases. Various

complications are seen in cases of *P. falciparum* malaria and that includes jaundice, metabolic acidosis, hyperlactataemia and hypoglycaemia along with pulmonary oedema, acute respiratory distress, as well as cardiac complications.<sup>4</sup> Myocarditis and cardiogenic shock as complication of *P. vivax* malaria is rarely described in world literature.

The exact mechanism by which these cardiac complications occur in malaria are still not clear. It is observed that sequestration related and non-sequestration related complications are seen in *P. vivax* malaria. Different mechanisms of pathogenesis of these complications can be described as in Figure 3.



Almost all cases that are reported of cardiac complications of Malaria were found to be *P. falciparum* malaria. The cardiac complications in *P. vivax* malaria, like in this case, are very rare. ECG and Echocardiography are useful diagnostic tests for detecting complications in cardiovascular system as well as to know the impairment of myocardial function.<sup>3</sup> These cardiac abnormalities sometimes persist even after the treatment of malaria is completed.<sup>5</sup>

The role of cytokines especially tumour necrosis factor (TNF) is important in pathogenesis of myocardial damage. It induces thrombospondin secretion leading to enhances

sequestration of parasitized red blood cells. Also overexpression of caspases and calpains is seen in presence of TNF and parasitized red blood cells but their exact role in causing cardiac myopathy is still unknown. An upregulation of myocardial damage marker N-terminal probrain natriuretic peptide (NT proBNP) suggests that glycosylphosphatidylinositol (GPI) probably induces apoptosis of cardiac myocytes and also leads to myocarditis.<sup>6</sup>

Certain cardiac markers that are found to be elevated in Malaria are listed in table 2. Conduction blocks as well as changes in T-ST are also seen in such cases, which clearly indicates that there is an alteration of electrophysiology of cardiac myocytes before the commencement of myocytosis.<sup>6</sup>

Table 2: Different markers that may be elevated in Malaria and are suggestive of cardiac complications.

Sr. No.	Marker	Elevated levels suggestive of
1	N-terminal probrain natriuretic peptide (NT proBNP)	Impaired left ventricular function
2	Heart-type fatty acid-binding protein (H-FABP)	Acute myocardial injury
3	Myoglobin & Creatine kinase muscle-brain (CK-MB)	Myocardial injury and necrosis
4	Cardiac Troponin T	Altered electrophysiology of cardiac myocytes
5	Glycosylphosphatidylinositol	Myocyte apoptosis & myocarditis
6	Soluble Vascular Cell Adhesion Molecule-1 (sVCAM-1)	Microvascular obstruction

Autopsy reports in many cases also support the micro-circulation blockage and subsequent ischaemic cardiomyopathy.<sup>5</sup> In cases of Malaria and Sickle cell anaemia, soluble vascular cell adhesion molecule-1 (sVCAM-1) levels are elevated. This helps in adhesion of both infected and non-infected red blood cells to endothelium leading to fibrin and platelet aggregation at that site, causing microvascular obstruction. Also elevated levels of Troponin T were seen in cases of *P. vivax* malaria suggesting myocardial injury.<sup>7</sup>

### Conclusion

In recent times, *P. vivax* malaria is manifesting with many uncommon complications which can prove to be fatal. The frequency of cardiac complications should not be underestimated in such cases. Early recognition of such complications is critical as delay in detection can lead to cardiogenic shock and even death. This case reveals that *P. vivax* infection can cause severe cardiac complications and the health service providers should be aware of such adverse events while treating patients with plasmodium infection.

### References

1. Nasir N, Lalani S, Samani ZA, Almas A (2014) Myocarditis complicating Plasmodium vivax malaria. *Journal of the College of Physicians and Surgeons – Pakistan*. 24; s96-98.
2. Ray HN, Doshi D, Rajan A, Singh AK, Singh SB, Das MK (2017) Cardiovascular involvement in severe malaria: A prospective study in Ranchi, Jharkhand. *Journal of Vector Borne Disease*. 54; 177-182.
3. Kumar S, Behera S, Khan AA (2017) Malarial Myocarditis: A Rare Complication of Plasmodium Vivax: Case Report. *Journal of Clinical Case Reports*. 7:3; 945.

4. Gupta N, Sahoo SK (2013) Plasmodium vivax induced myocarditis: A rare case report. *Indian Journal of Medical Microbiology*. 31:180-1.
5. Mohsen AH, Green ST, West JN, McKendrick MW (2001) Myocarditis Associated with Plasmodium falciparum Malaria: A Case Report and a Review of the Literature. *Journal of Travel Medicine*. 8:4; 219-220.
6. Costenaro P, Benedetti P, Facchin C, Mengoli C, Pellizzer G (2011) Fatal Myocarditis in Course of Plasmodium falciparum Infection: Case Report and Review of Cardiac Complications in Malaria. *Case reports in Medicine*. 2011:1-5.
7. Alencar-Filho AC, Ferreira JMMB, Salinas JL, Fabbri C, Monteiro WM, Siqueira AM et al. (2016) Cardiovascular changes in patients with non-severe Plasmodium vivax malaria. *International Journal of Cardiology Heart & Vasculature*. 11:12-16.

---

**How to citation this article:** Dr. Gaurav Y. Lakhani, Dr. Pooja S. Zanzari, Dr. Priyanka R. Patel, Dr. Anuj V. Mansata, "Myocarditis and Cardiogenic Shock Associated with Plasmodium Vivax Malaria: A Rare Case Report", *IJMACR- November - December - 2020, Vol – 3, Issue - 6, P. No. 54 – 57.*

**Copyright:** © 2020, Dr. Gaurav Y. Lakhani, et al. This is an open access journal and article distributed under the terms of the creative commons attribution noncommercial License 4.0. Which allows others to remix, tweak, and build upon the work non-commercially, as long as appropriate credit is given and the new creations are licensed under the identical terms.

---