

Pediatric Zirconia Crown: Reason for Kedo Smile

¹Dr. Apexa Yadav, MDS, Consultant Pediatric Dentist, Bharuch, Gujarat

²Dr. A. Thirumagal Anuraaga, Postgraduate student, Department of Pedodontics and Preventive Dentistry, Sri Siddhartha Dental College and Hospital, Tumkur

³Dr. Gowri Sarvani Sistla, MDS, Senior Resident, Department of Pediatric and Preventive Dentistry, Government Dental College, Hyderabad

⁴Dr. Milind Rajan, Postgraduate student, Department of Pedodontics and Preventive Dentistry, Coorg Institute of Dental Sciences, Virajpet, Karnataka

⁵Dr. Niharika Sharma, Postgraduate Student, Department of Pediatric and Preventive Dentistry, Kothiwal Dental College and Research Centre, Moradabad, Uttar Pradesh

⁶Dr. Bidyut Seal, MDS, Pediatric and Preventive Dentistry, Private practitioner, Goalpara, Assam

Corresponding Author: Dr. Apexa Yadav, MDS, Consultant Pediatric Dentist, Bharuch, Gujarat

How to citation this article: Dr. Apexa Yadav, Dr. A. Thirumagal Anuraaga, Dr. Gowri Sarvani Sistla, Dr. Milind Rajan, Dr. Niharika Sharma, Dr. Bidyut Seal, “Pediatric Zirconia Crown: Reason for Kedo Smile”, IJMACR- September – October - 2021, Vol – 4, Issue - 5, P. No. 160 – 164.

Copyright: © 2021, Dr. Apexa Yadav, et al. This is an open access journal and article distributed under the terms of the creative commons attribution noncommercial License 4.0. Which allows others to remix, tweak, and build upon the work non-commercially, as long as appropriate credit is given and the new creations are licensed under the identical terms.

Type of Publication: Original Research Article

Conflicts of Interest: Nil

Abstract

Early childhood caries is a complex disease affecting the primary teeth for which parents often seek treatment. The management often includes alleviation of infection and reestablishment of form and function using full coronal restorations. Stainless steel crowns are one of the earliest crowns used in dentistry to restore teeth. The only disadvantage of SSC was its unaesthetic appearance. Recently, zirconium dioxide ceramic prefabricated crown has been used in the treatment of primary teeth. The choice of full coverage restoration for primary teeth must provide an esthetic appearance in addition to restoring function and durability. This review throws light on clinical use of zirconia crown in pediatric dentistry.

Keywords: Zirconia crown, Esthetic, ECC

Introduction

Infants and toddlers with caries experience have a high risk for subsequent caries in primary and permanent dentition as well. The consequence of Early childhood caries results are destruction of primary maxillary incisors, which further effect the chewing efficiency, loss of height, development of tongue-thrusting and/or mouth-breathing, speech disturbances, and psychological behavioural complications. Therefore, integrity of the primary dentition should be preserved until they exfoliate normally.¹

The management often includes alleviation of infection and reestablishment of form and function using full

coronal restorations. Stainless steel crowns (SSC) were the choice of full coronal restoration, as they were easily available as pre-formed, pre-trimmed and pre-contoured crowns with wide range of sizes and with proven clinical efficiency. The only disadvantage of SSC was its unaesthetic appearance.^{2,3}

More esthetic demand of the parents and patients for restoration of the decayed and damaged primary teeth has led to the availability of different esthetic preformed crowns. For pediatric dentists, the esthetic rehabilitation of severely damaged deciduous teeth is one of the greatest challenges. Various techniques have been attempted over the years in restoring the teeth. Some of them are polycarbonate crowns, acid-etched crown, stainless steel crown, strip crowns, open-faced SSC with veneer placed on chair side, and commercially available pre-veneered SSC. The viable and productive use of these strategies is convoluted because of technical, utilitarian, or esthetic hurdles.^{4,5}

The technological advances in techniques and material science led to the evolution of preformed Zirconia crowns for primary teeth, so as to fulfil the esthetic demands, at the same time promise good durability. Zirconia crowns are known as “Ceramic Steel” as it provides strength close to available metal crowns as well as colour similar to that of natural teeth. Pediatric zirconia crowns were introduced by EZ-pedo and became commercially available in 2008. Later preformed zirconia crowns were popularized by companies like Nusmile, Kinder crowns, Cheng crowns, Signature crowns and many more.⁶ These preformed crowns differed with respect to size, shape, shade and pattern of retention component.

History of Pediatric Zirconia Crown

In 2004, Hansen’s 3-year-old son, John Paul, fell in the bathtub and seriously injured four of his front teeth.

Hansen sent his son to a pediatric dentist to have the boy’s smile reconstructed and was stunned to learn that there were noesthetically pleasing crowns like those typically custom-crafted for adults. Hansen said the crowns placed on his son’s teeth were bulky, did not match in colour and presented a smile that showed metal at the gumline. Then Hansen thought of making esthetic crowns for children. Local dentists Jeff Fisher and John Hansen did years of research with local dentists before founding all ceramic crown; EZ-Pedo Inc., in Loomis, California, in 2010. Jeffrey P Fisher and John P Hansen of Sacramento, California, started EZ-Pedo Inc. in 2010, and today their relatively small manufacturing site in Loomis, California, produces thousands of ceramic dental crowns for children. EZ-crowns got clearance from US Food and Drug Administration and clearance from FDA for use in 2009. The company states that, it had about 10 percent of the US nation’s pediatric crown market.^{7,8}

Table 1: Different Pediatric Zirconia Crown Available In Market	
Brand Name	Company
NuSmile Zirconia Crown	NuSmile Ltd.
Cheng Zirconia Pediatric crowns	Cheng Crowns
Kids E Crown	Kids E Dental
Signature Preformed Zirconia Crown	3M
Zirconia Kinder Krown	Kinder Krown

Clinical Procedure: The tooth preparation and crown placement for anterior and posterior teeth are similar to that for SSC, i.e.

- Crown selection
- Tooth preparation-on lingual , incisal, facial, proximal surfaces
- Checking for crown fit and crown cementation.⁸

In case of crown placement, tooth preparation and cementation procedures are the two important steps.

Adequate clearance, proper angulations, and knife edge finish lines are necessary to preserve gingival health and promote less plaque accumulation.⁴

Adequate preparation of the tooth will fundamentally improve esthetics; crown fit reduces chances of crack and saves chairside time. The tooth must be prepared to fit the crown, so the crown fits the tooth inactively without utilizing pressure. The preparation of tooth takes more time for zirconia crowns and it is difficult to adjust a zirconia crown since it is ceramic and cannot be trimmed with scissors like the SSC. Hence, it is mandatory to use a high-speed, fine diamond bur with plenty of water since excessive heat can create fractures in the ceramic structure of the crown.⁴ Occlusal and proximal adjustments are not recommended, because it might affect the crown's glaze and create a weak area of thin ceramic. Zirconia crowns should fit passively and do not try to seat the crown with force, because it will result in the fracture of the crown as they are made up of solid zirconia.

The appropriate size of the crown should be in such a way that it fit passively and subgingivally without distorting the gingival tissue.^{9,10} Zirconia crown size was selected by placing the incisal edge of the zirconia crown against the incisal edge of the tooth.⁴

The manufacturers of the NuSmile ZR crown have provided tooth preparation guidelines on their website, where they recommend a reduction of 1–2 mm on the occlusal surface, maintaining the natural contour; a 0.5–1.25 mm circumferential reduction; and a feather edge of approximately 1–2 mm subgingivally.¹¹

Kids-e-crown recommends 1.5-2 mm incisal/occlusal reduction followed by Creating chamfer margin all around the tooth by reducing 0.5 – 1mm. Later on chamfer margin is removed and extend 2 mm subgingivally without ledge formation.¹²

After completion of the crown preparation selected preformed crown is placed on the prepared tooth. Passive fit of the crown and occlusion is checked and then crown is luted with dual cure resin cement or glass ionomer cement. Consistent firm finger pressure is applied during cementation. Care is taken to stabilize the crown in position^{4,8} till the cement has completely hardened.

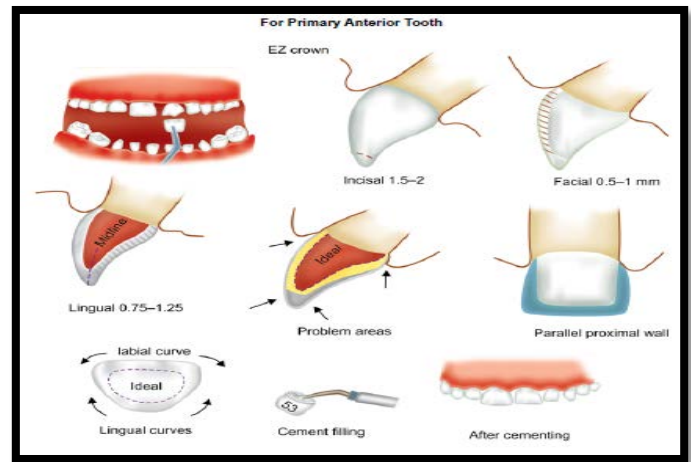


Figure 1: Clinical Steps in Pediatric Zirconia Crown Placement

Figure source: Babaji P. Crowns in Pediatric Dentistry. 1st ed. Jaypee Pub Ltd; 2015

Discussion

Full coronal restorations have become the prevalent part of rehabilitation of the children affected with early childhood caries. Multiple options have been tried with each one showing varied clinical performance. Change in life style, more opportunities to socialize and role of media plays a role in exposing the children to a concept of ideal beauty at very young age. This has showed impact on their concerns about esthetics which is similar to that of adults⁸. The same principle applies in terms of restorations to be placed on their teeth.^{13,14}

Zirconia crowns were introduced to pediatric dentistry as an alternative restorative option. Advantages of the pediatric zirconia crowns included: excellent esthetics,

resistance to fracture, biocompatibility, reduced plaque accumulation, colour stability, and potentially less technique sensitivity. Excellent esthetics was reported by clinicians and parents. Biocompatibility and reduced plaque accumulation were found to be due to the polished surface of zirconia crowns leading to less gingival inflammation, when compared to veneered stainless-steel crowns.^{15,16}

Tooth preparation and cementation procedure are important clinical steps in a crown placement. The presence of adequate clearance, proper angulations, and visible knife edge finish lines helps to preserve gingival health and less plaque accumulation. Adequate preparation of the tooth will significantly improve esthetics; crown fit reduces chances of veneer fracture and saves chair time. The tooth should be prepared to fit the crown so that the crown fits the tooth passively without using pressure. The preparation of tooth for zirconia crown takes more time, and so this crown not recommended for children who are fearful and unable to cooperate for longer procedures.^{9,10}

Some drawbacks which limit the use of zirconia crowns are that it requires significantly more time to prepare the tooth for fitting the crown. Bleeding from the gum, due to anxiety or inflammation, may hinder the setting of the cement used to bond the zirconia crown to the tooth.¹⁷

Another major concern in utilizing these crowns was the propensity towards expanded wear on the antagonist teeth as seen by Walia et al.¹⁸

Conclusion

Esthetics has become a respectable concept in dentistry today. Prefabricated zirconia crowns could be an esthetic, restorative option to traditional stainless steel and composite strip crowns due to their unparalleled advantages. Zirconia crowns offer high-end esthetics,

superior durability, and easy placement compared to composite restorations and strip crowns.

References

1. Eshghi A, Kowsari-Isfahan R, Khoroushi M. Evaluation of three restorative techniques for primary anterior teeth with extensive carious lesions: a 1-year clinical study. *J Dent Child (Chic)*. 2013 ;80(2):80-7.
2. Clinical AC, American Academy of Pediatric Dentistry. Guideline on pediatric restorative dentistry. *Pediatric dentistry* 2012;34(5):173.
3. Abdulhadi BS, Abdullah MM, Alaki SM, Alamoudi NM, Attar MH. Clinical evaluation between zirconia crowns and stainless steel crowns in primary molar teeth. *Journal of Pediatric Dentistry* 2017 Jan 1;5(1):21.
4. Khatri A. Esthetic zirconia crown in pedodontics. *Int J Pedod Rehabil* 2017;2(1):31–33.
5. Waggoner WF, Cohen H. Failure strength of four veneered primary stainless-steel crowns. *Pediatr Dent* 1995;17:36–40.
6. Tote J, Gadhane A, Das G, Soni S, Jaiswal K, Vidhale G. Posterior Esthetic Crowns in Pediatric Dentistry. *Int J Dent Med Res*. 2015;1(6):197-201.
7. <http://www.ezpedo.com>.
8. Babaji P. *Crowns in Pediatric Dentistry*. 1st ed. Jaypee Pub Ltd; 2015.
9. Karaca S, Ozbay G, Kargul B. Primary zirconia crown restorations for children with early childhood caries. *Acta Stomatol Croat* 2013;47(1):64–71.
10. Soxman JA. *The Handbook of Clinical Techniques in Pediatric Dentistry*. Hoboken: Wiley-Blackwell; 2015. pp. 47–50.
11. NuSmile website. Available at: http://www.nusmilecrowns.com/new_ZR.aspx.pdf Accessed January 12, 2020.

12. <http://kids-e-dental.com/>
13. Pani SC, Saffan AA, AlHobail S, Bin Salem F, AlFuraih A, AlTamimi M. Esthetic concerns and acceptability of treatment modalities in primary teeth: a comparison between children and their parents. *Int J Dent*. 2016
14. Fishman R, Guelmann M, Bimstein E. Children's selection of posterior restorative materials. *J Clin Pediatr Dent*. 2007 Sep 1;31(1):1-4
15. Mittal G, Verma A, Pahuja H, Agarwal S, Tomar H. Esthetic crowns in pediatric dentistry: a review. *International Journal of Contemporary Medical Research*. 2016; 3(5):1280-1282.
16. Sahana S, Vasa AAK, Ravichandra SK. Esthetic Crowns for Anterior Teeth: A Review. *Annals and Essence of Dentistry*. 2010-2, 87-93.
17. Ajayakumar LP, Chowdhary N, Reddy VR, et al. Use of Restorative Full Crowns Made with Zirconia in Children: A Systematic Review. *Int J Clin Pediatr Dent* 2020;13(5):551–558.
18. Walia T, Salami AA, Bashiri R et al. A randomized controlled trial of three aesthetic full-coronal restorations in primary maxillary teeth. *Eur J Paediatr Dent* 2014;15(2):113–118.