

### **Botulinum Toxin-A Treatment for Facial Esthetic**

<sup>1</sup>Prof. Dr. Sonal Madan, Professor, Department of Oral and Maxillofacial Surgery, College of Dental Sciences and Research Centre, India

<sup>2</sup>Prof. Dr. Kiran Patel, Professor, Department of Oral and Maxillofacial Surgery, College of Dental Sciences and Research Centre, India

<sup>3</sup>Dr. Setu P. Shah, Reader, Department of Oral and Maxillofacial Surgery, College of Dental Sciences and Research Centre, India

<sup>4</sup>Dr. Bhargav Gupta, MDS, Department of Oral and Maxillofacial Surgery, College of Dental Sciences and Research Centre, India

<sup>5</sup>Dr. Shalin Shah, Sr. Lecturer, Department of Oral and Maxillofacial Surgery, College of Dental Sciences and Research Centre, India

<sup>6</sup>Dr. Aarti Mali, Resident II P.G., Department of Oral and Maxillofacial Surgery, College of Dental Sciences and Research Centre, India

**Corresponding Author:** Dr. Aarti Mali, Resident II P.G., Department of Oral and Maxillofacial Surgery, College of Dental Sciences and Research Centre, India

**How to citation this article:** Prof. Dr. Sonal Madan, Prof. Dr. Kiran Patel, Dr. Setu P. Shah, Dr. Bhargav Gupta, Dr. Shalin Shah, Dr. Aarti Mali, “Botulinum Toxin-A Treatment for Facial Esthetic”, IJMACR- January – February - 2022, Vol – 5, Issue - 1, P. No. 193 – 198.

**Copyright:** © 2022, Dr. Aarti Mali, et al. This is an open access journal and article distributed under the terms of the creative commons attribution noncommercial License 4.0. Which allows others to remix, tweak, and build upon the work non-commercially, as long as appropriate credit is given and the new creations are licensed under the identical terms.

**Type of Publication:** Original Research Article

**Conflicts of Interest:** Nil

### **Abstract**

**Background:** Muscular facial activity and its relationship to the formation of wrinkles is one of the major forces responsible for facial aging process. Botox is a toxin made by the bacteria Clostridium Botulinum that paralyzes muscles by suppressing acetylcholine release at the neuromuscular junction. When Botulinum Toxin-A (BTX-A) employed in hyper functional muscle groups like procerus, corrugator, orbicularis oculi and depressor supercilia there is a transitory partial paralysis, which reduces wrinkled appearance. The purpose of this

study was to evaluate the effects of the BTX-A into glabellar area, forehead wrinkles and crow’s feet by injecting the solution in a prescribed manner.

**Material and method:** This randomized prospective study consisted of 10 patients with facial ageing complains. They received intradermal injection of BTX-A in upper face region and patients were followed up for regular intervals up to the 12 months.

**Result:** In the area of transverse glabellar lines, after injecting BTX-A solution inflammation of skin was not observed but in the area of vertical glabellar lines,

forehead creases and crow's feet immediately after injecting solution red and inflamed areas were noticed. Post operatively, on 3 months follow up, a wrinkle-free area was observed and between 6 to 12 months follow up, there was a steady increase in the number of wrinkles as well as in their depth.

**Conclusion:** In the field of face plastic surgery, BOTOX has shown to be safe and effective for a variety of clinical indications. BTX-A injections for facial rhytids have become one of the most popular non-invasive procedures in facial plastic surgery, with a very high patient satisfaction rate. Although there are some risks to be aware of, the majority of individuals respond effectively to this treatment.

**Keywords** – Ageing, Botox, Facial Aesthetics, Injection, Rejuvenation

### **Introduction**

For identification and discrimination, the face remains the most important source of data. It serves as a structural foundation for numerous nonverbal messages, including a person's emotional condition, proving the saying "Face is an indication of mind." One of the things that contribute to ageing is wrinkles and laxity.<sup>[1]</sup>

Dynamic wrinkles in the perioral, glabellar, and forehead regions (produced by hyper functional muscles) might lead a patient's expressions to be misunderstood as angry, nervous, afraid, or exhausted. The use of a paralyzing agent is a new therapy option for these problems. BTX-A is a substance that is used to reduce the appearance of wrinkles, which yields a more aesthetic and young aspect of the face.<sup>[2]</sup>

There are two types of rhytids, or wrinkles: dynamic and static. Dynamic wrinkles appear when muscles contract, and they are especially noticeable in the forehead and periorbital areas of the face. They are the result of the

underlying muscles of facial expression being repeatedly and habitually contracted. Wrinkle is a line stays entirely within the epidermis and does not extend into the skin's dermis. Skin texture, amount of subcutaneous fat, water content of the skin, distribution and ratio of collagen and elastic fibres, biochemical changes in the connective tissue, and interstitial spaces are six factors that might alter the depth of a wrinkle. Aging, photodamage, trauma, or scarring can all cause static wrinkles.<sup>[2]</sup>

Today Botox is the most commonly performed cosmetic procedure throughout the world.<sup>[3]</sup> Botox is prepared by laboratory fermentation of *Clostridium Botulinum*, which lyses and liberates the toxin into culture. The toxin is then harvested, purified, crystallized with aluminium sulphate, diluted in serum albumin, lyophilized, bottled in vials, and sealed.<sup>[4]</sup>

### **Materials and methods**

This study was conducted and performed in the Department of Oral and Maxillofacial Surgery in College of Dental Science and Research Centre, Ahmedabad, Gujarat, after getting approval from ethical committee. In total, 10 patients were involved in the study with facial ageing complains. The study group had a age range between 30 to 50 years, of whom 4 subjects were female, and 6 were male. Patients with hyper functional facial lines in the region of the glabella, forehead lines and crow's feet were included in the study. Patients with age group below 14 years; patients with history of allergic to BTX-A; females during pregnancy or lactation were excluded from the study. The purpose of this study was to evaluate effects of the Botox into glabellar, forehead and crow's feet wrinkles by injecting BTX-A in a prescribed manner.

Before starting procedure patient's detailed medical examination and complete facial assessment was

undertaken. Patient's facial anatomy prior to treatment was studied. Pre-treatment photography was highly recommended, A proper written informed consent was obtained specific to the areas of treatment and mentioned with post operative complications, such as headache, flu-like symptoms, bruising, infection, eyelid drooping, smile asymmetry, speech enunciation changes, and dysphagia.<sup>[5]</sup>

#### Armamentarium:

1. Alcohol pad (2% isopropyl alcohol).
2. Topical skin anaesthetic agent (20% benzocaine gel).
3. Marking pen.
4. Insulin syringe.
5. Allergen BTX-A vial.

#### Injection Technique

The procedure started with dilution of BTX-A vial. 2.5 ml of 0.9% sterile, non-preserved normal saline mixed with 50U of BTX-A vial. The location, size, and power of the muscles in the glabellar wrinkles, forehead creases, and crow's feet were assessed prior to therapy. A marking pen was used to mark the injection sites (Fig. 1). Prior to the injection, the injection sites were disinfected with 2% isopropyl alcohol. 20 % benzocaine gel was used as a topical skin anaesthetic.

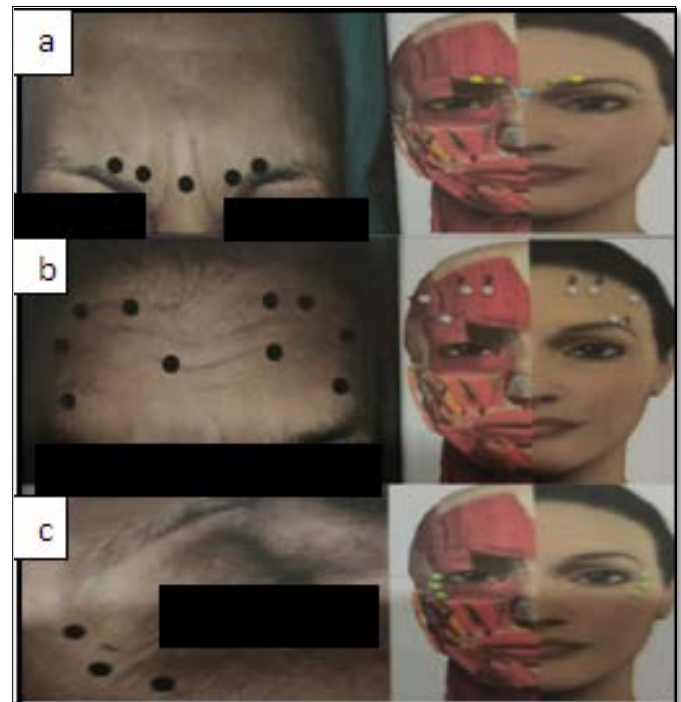


Figure 1: Injection sites(a) glabellar frown line, (b) horizontal forehead lines, (c) the lateral canthal lines (crow's feet).

#### Glabellar Frown Lines

Patients were asked to frown and scowl, and target muscles were palpated to determine location, size and power of muscles. 5 sites were marked with marking pen (Fig. 1a) and BTX-A was injected with 4-6 units each for an average total dose of approximately 25 units. First, needle was inserted at the origin of the corrugator fibers until the bone was felt and then withdraw the needle slightly. The needle was then advanced within belly of muscle upward and lateral as far as the middle third of the eyebrow, 1 cm superior to orbital rim. 4-6 units were injected as the needle was withdrawn. 1 cm above the upper medial aspect of supraorbital ridge, the needle was advanced slightly in vertical direction toward hair line. 4-6 units were injected into orbicularis oculi and depressor supercilia as the needle was withdrawn. Lastly, 4-6 units were injected into the centre belly of

the procerus in the centre of nasal root, just superior to horizontal plane of medial canthi. (Fig. 2 a)

#### **Horizontal Forehead Lines**

In this region 3-5 sites on each side of midline were injected using 2 units per site (Figure 1.b). The lowest crease is identified and marked. The initial injection site was at lowest crease line approximately 1 cm above the eyebrow directly above the medial canthus. Additional sites were separated by 1-2 cm, diverge laterally and upward to the hairline in “V” configuration. (Fig. 2 b)

#### **Lateral Canthal Lines (Crow’s Feet)**

In the lateral canthal lines (crow’s feet), medial and lateral extent of wrinkles were evaluated (Figure 1.c). A snap back test or lower retraction test performed to assess the lower lid resiliency. 3-4 subcutaneous injections were applied, approximately 1 cm lateral to the lateral orbital rim, using 2-3 units per injection site (total of 6- 12 U per side). Sites were spaced 2 cm apart in vertical line or slightly curving arch. Patients were advised to close the eyes during entire procedure. (Fig. 2 c)

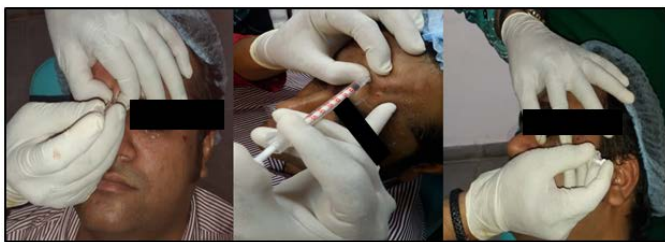

Figure 2: Injection procedure (a) glabellar frown line, (b) horizontal forehead lines, (c) the lateral canthal lines (crow's feet).

#### **Results**

**Glabellar Frown Lines:** Immediately after injecting BTX-A, in area of transverse glabellar frown lines, there were no marks or any inflamed skin. Maximum reduction in specific muscle functions after 2 weeks, and absolutely no wrinkles were seen after 3 months follow

up. Between 6 months to 12 months follow up, there was increased in number and depth of wrinkles along with redundant skin were observed.

Red marks were observed over injection sites in the area of vertical glabellar lines immediately after injecting BTX-A. The function of the targeted muscles was reduced partially after 2 days and completely after 2 weeks. During the 2 weeks to 3 months follow-up period, no significant differences were found. After 6 months, there were moderate numbers of creases with moderate depth. After 12 months, there was an increase in the number of deep wrinkles as well as redundant skin.

**Horizontal Forehead Lines:** In area of horizontal forehead creases after injecting BTX-A there were tiny bumps or marks were observed. After 2 days, there was a partial reduction in function, and after 2 weeks, there was a maximum reduction in function of the targeted muscles. After 3 months follow up, the wrinkle-free area was seen. 6 to 12 months following injections, the depth and number of wrinkles, as well as skin laxity, gradually increased.

**Lateral Canthal Lines (Crow’s Feet):** Immediately after injecting BTX-A in this region red and inflamed patches were observed. After 2 days, there was no effect of BTX-A, and after 2 weeks, there was a maximum decline in the function of the targeted muscles. After 3 months follow up, the wrinkle-free area was observed. 6 to 12 months following injections, there was a consistently increased in the number of wrinkles and their depth. (Fig. 3).

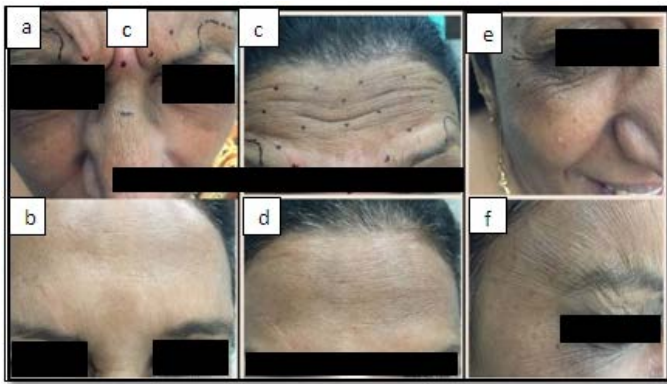

Figure 3: Clinical photographs: (a) glabellar frown lines pre-operative, (b) glabellar frown lines post-operative, (c) horizontal forehead lines pre-operative, (d) horizontal forehead lines post-operative, (e) crow's feet lines pre-operative and (f) crow's feet lines post-operative.

### Discussion

In humans, the neuromuscular junction (NMJ) or end motor plates have been found to be located at the midpoint of each muscle fiber, forming distinct cluster called NMJ zone or end plate zone. Botulinum toxin, the most potent of the neurotoxins, produces paralysis by blocking presynaptic release of the neurotransmitter (acetylcholine) at the neuromuscular junction, with reversible chemical denervation of the muscle fibre, thereby inducing partial paralysis and atrophy. Because chemical denervation is reversible, botulinum toxin has temporary effects, the muscle being progressively reinnervated by nerve sproutings.<sup>[6]</sup> Botox is a highly effective muscle relaxant. One of the most typical applications is to inject near wrinkles to make them disappear.

The application of a paralyzing substance, such as BTX-A, to decrease the appearance of the wrinkles, which yields a more aesthetic and youthful facial appearance. The number of injection sites may also differ depending on the muscle size. In small muscles, larger doses increase the likelihood of spreading into adjacent

muscles. Larger doses may be required in larger muscles, and splitting the dose along the presumed end plate zone may improve the impact.

Farahvash MR. and Arad S. conducted a study on 108 patients and concluded that glabellar frown lines, horizontal frontal lines and crow's feet can be treated by direct injection of BTX-A and also concluded that BTX-A seemed to be a safe and effective, giving good to excellent cosmetic results lasting at least 4 months in the majority of the patients.<sup>[7]</sup>

Injections closer to the brows in the glabellar region may increase the likelihood of BTX-A migration into the orbit and denervation of the levator palpebral muscle, resulting in eyelid ptosis. Ptosis was detected in two cases despite proper management. Ptosis was caused by the patient rubbing around the injection site, which disseminated the BTX-A solution near the levator palpebral muscle, despite pre-operative instructions.<sup>[1,8]</sup> This condition was resolved after 2 weeks, no further therapy was required. Individuals with heavy horizontal forehead creases were the best subjects for treatment. Care was taken to not deposit excessive amounts of BTX-A over the lateral brow, which might cause a drop in the lateral brow position and flattened brow.<sup>[1,9]</sup>

Diplopia is the most common complication for crow's feet in the lateral canthal area. Diplopia is caused by 2 factors: (1) Placing BTX-A deep to orbital septum which could migrate toward ocular muscles. We have taken care not to inject more than 2 mm depth. (2) Over infusion of BTX-A in ocular muscles, so prevent that we have taken care keeping injection site 1.5-2 cm away from lateral canthus.

Other dose-dependent anti-neuroinflammatory effects and vascular modulating properties of Botulinum toxins have extended its spectrum of applications. Conditions

such as temporomandibular joint disorders, sialorrhea, headache, masseteric and temporalis muscle hypertrophy, neuropathic facial pain, neuromuscular disorders, facial nerve palsy, keloid and hypertrophic scar could also be treated with this drug.<sup>[10]</sup>

BTX-A injections have the following advantages over facial plastic surgery: Inexpensive, relatively non-invasive, requiring only few pin-pricks, taking about only 15 minutes for the procedure, virtually has no recovery time, allowing patients to return to work on same day, effectively treats mild to moderate wrinkles, can completely erase fine lines, but only soften deep wrinkles. Botox is not permanent and may need re-treatment can be done every 4-6 months.

### Conclusion

Patients are increasingly seeking not only perfect function and aesthetics from their teeth, but also macroesthetics augmentation. Treatment of hyper functional facial wrinkles with Botox can produce a very aesthetic end effect. The BTX-A injection approach is safe, effective, predictable, minimally invasive, and reproducible in the treatment of facial aesthetics. Understanding the treatment's limitations and being able to recognize and handle problems are critical. Maxillofacial surgeons who have extensive knowledge of facial anatomy, giving them a significant advantage in case selection and treatment. This therapy modality may offer a feasible non-surgical option for rejuvenating the ageing face if administered by skilled individuals on carefully selected patients. However, long term study with larger sample size is essential for better perspective on promise of this treatment modality.

### References

1. Dayan S, Benjamin BA. Evaluation of the patients for cosmetic botox injections. *Facial Plast Surg Clin North Am* 2003;11:349-58.
2. Dastoor SF, Misch CE, Wang HL. Botulinum toxin (Botox) to enhance facial macroesthetics: a literature review. *J Oral Implantol* 2007;33(3):164-71.
3. Beer, Kenneth, Cohen, Joel, Carruthers, Alastair. Cosmetic uses of botulinum toxin A. *Clinical uses of botulinum toxins*. Cambridge University Press 2007:328-48.
4. Vigliante CE. Anatomy and functions of the muscles of facial expression. *Oral Maxillofac Surg Clin North Am* 2005;17(1):1-5.
5. Bakheit AM. The possible adverse effects of intramuscular botulinum toxin injections and their management. *Curr Drug Saf* 2006;1(3):271-9.
6. Laguény A, Burbaud P. Mechanism of action, clinical indication and results of treatment of botulinum toxin. *Neurophysiol Clin* 1996;26(4):216-26.
7. Farahvash MR, Arad S. Clostridium botulinum type A toxin for the treatment of upper face animation lines: an Iranian experience. *J Cosmet Dermatol* 2007;6(3):152-8.
8. Bassichis BA, Thomas JR. The use of Botox to treat glabellar rhytids. *Facial Plast Surg Clin North Am* 2003;11(4):453-6.
9. Vartanian AJ, Dayan SH. Complications of botulinum toxin A use in facial rejuvenation. *Facial Plast Surg Clin North Am* 2003 Nov;11(4):483-92.
10. Majid OW. Clinical use of botulinum toxins in oral and maxillofacial surgery. *Int J Oral Maxillofac Surg* 2010;39(3):197-207.