

## Immunohistochemical analysis of round cell tumour in tertiary care hospital

<sup>1</sup>Dr. Reeta Kataruka, Associate Professor, Department of Pathology, MGM Medical College, Aurangabad, Maharashtra.

<sup>2</sup>Dr. Purva More, Resident, Department of Pathology, MGM Medical College, Aurangabad, Maharashtra.

<sup>3</sup>Dr. Chandrashekhar Bhale, Professor and Head of the Department, Department of Pathology, MGM Medical College, Aurangabad, Maharashtra.

**Corresponding Author:** Dr. Purva More, Resident, Department of Pathology, MGM Medical College, Aurangabad, Maharashtra.

**How to citation this article:** Dr. Reeta Kataruka, Dr. Purva More, Dr. Chandrashekhar Bhale, “Immunohistochemical analysis of round cell tumour in tertiary care hospital”, IJMACR- January – February - 2022, Vol – 5, Issue - 1, P. No. 212 – 216.

**Copyright:** © 2022, Dr. Purva More, et al. This is an open access journal and article distributed under the terms of the creative commons attribution noncommercial License 4.0. Which allows others to remix, tweak, and build upon the work non-commercially, as long as appropriate credit is given and the new creations are licensed under the identical terms.

**Type of Publication:** Original Research Article

**Conflicts of Interest:** Nil

### Abstract

**Background:** Immunohistochemistry (IHC) plays a very important role in the identification of tumours that lacks the differentiation on the basis of routine Haematoxylin and Eosin stain. The aim of our study is to analyse the small round cell tumours in histopathology on the basis of IHC.

### Objective

- To assess the histomorphological diagnosis with IHC pattern of round cell tumours
- To correlate the IHC with histopathological diagnosis

**Materials and methods:** This is a retrospective study done from 2018 to April 2021. Total 44 cases of small round cell tumours were studied in department of Pathology and was sent outside for IHC confirmation.

**Results:** Out of 44 cases there were 15 cases of Neuroendocrine, 13 cases of Non-Hodgkin Lymphoma

(NHL), 6 cases of Hodgkin Lymphoma (HL), 3 cases of Pheochromocytoma, 3 cases of small cell carcinoma, 1 case of Alveolar Rhabdomyosarcoma (ARMS) and 1 case of Neuroblastoma.

Common IHC panel for Neuroendocrine: Synaptophysin, chromogranin, Ki 67, Pan CK; NHL: CD20, CD45, Pax5, Bcl2, Bcl6, Mum1, Ki67; HL: CD15, CD30, Pax5, Ki67; Pheochromocytoma: Synaptophysin, Chromogranin, Ki67; Small cell carcinoma: Synaptophysin, chromogranin, Pan CK, CK7; Paraganglioma: CK, Vimentin, S100, PAS, Chromogranin; ARMS: Desmin, Myogenin, Ki67; Neuroblastoma: CD56, Vimentin, Synaptophysin, Chromogranin, Ki67.

**Conclusion:** IHC plays an important role in treatment, diagnosis and typing of small round cell tumours. Histopathology helps in deciding the tailor made IHC panel of round cell tumour.

**Keywords:** Immunohistochemistry, round blue cell tumours, histomorphology, Ki67.

## Introduction

Small round cell tumour is highly aggressive malignant tumours which are relatively small, monotonous and undifferentiated cells with high nuclear-cytoplasmic ratio. <sup>(1)</sup>

Small round cell tumours are heterogenous malignancy mostly seen in children, adolescents, and young adults which involves the skeletal system or soft tissue. <sup>(2)</sup>

Tumours that show good differentiation are generally easy to diagnose, but when a tumour is poorly differentiated, identification of morphological features is difficult. <sup>(3)</sup>

They show histological similarity and so the differentiation becomes difficult on hematoxylin and eosin (HE) sections hence it becomes difficult to make a definite diagnosis, and requires the additional support of immunohistochemical (IHC) and molecular studies. <sup>(4)</sup>

Some of the differential diagnosis for malignant small round cell tumour are Non-Hodgkin Lymphoma, Hodgkin Lymphoma, Lymphoblastic Lymphoma, Retinoblastoma, Pheochromocytoma, Small cell carcinoma, Neuroendocrine, Rhabdomyosarcoma, Hepatoblastoma, Neuroblastoma, Synovial Sarcoma, Ewing Sarcoma, Undifferentiated Neuroendocrine carcinoma, Osteosarcoma, Wilms tumour. <sup>(5-7)</sup>

It is important to differentiate whether the tumour is epithelial, mesenchymal, neuroendocrine, melanocytic, and hematopoietic for treatment and prognostic purpose. Treatment include surgery, radiotherapy, chemotherapy or combination depending upon the tumour. For example, chemotherapy is used to treat Ewing's Sarcoma, Osteosarcoma, Rhabdomyosarcoma. Squamous cell carcinomas are treated with radiotherapy

while adenocarcinomas require primary surgery as they are not that radiosensitive <sup>(3)</sup>.

## Aims and Objectives

- 1) To assess the histomorphological diagnosis with IHC pattern of round cell tumours
- 2) To correlate the IHC with histopathological diagnosis

## Materials and Methods

This is a retrospective descriptive study carried out in Department of Pathology, MGM Medical College And Hospital Aurangabad, done from 2018 to April 2021.

Total 44 cases of small round cell tumour were studied. Histopathological parameters were studied on biopsy fixed in 10% neutral formalin, embedded in paraffin wax and stained with hematoxylin and eosin. <sup>(8-9)</sup>

Slide examination for architecture and pattern of tumour cells, morphology of cells with nuclear and cytoplasmic characteristics, haemorrhage, calcification, presence of mitosis, necrosis, presence or absence of rosettes or pseudo rosettes was done.

The tissue block was then outsourced for IHC.

IHC findings were then correlated with the histopathological findings and tried to make the common IHC panel for round cell tumour.

## Results

Small round cell tumours are a heterogenous group of malignant neoplasms.

In our study out of total 44 cases with male predominance, most higher incidence noted is Neuroendocrine (15 cases) followed by Non-Hodgkin Lymphoma (13 cases), Hodgkin Lymphoma (6 cases), Pheochromocytoma (3 cases), Small cell carcinoma (3 cases), Alveolar Rhabdomyosarcoma (1 case), Neuroblastoma (1 case). (Figure 1, Table 1)

Figure 1: Round blue cell tumours.

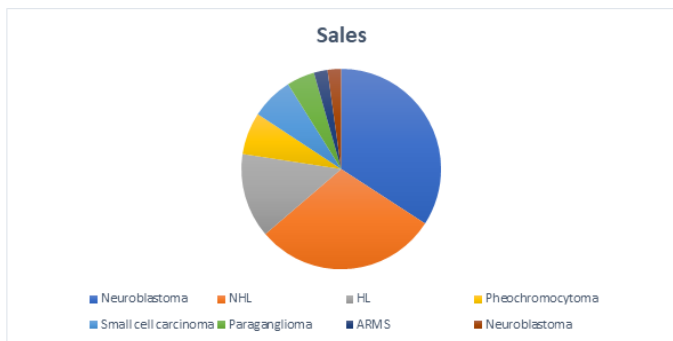


Table 1: Round blue cell tumours.

Final Diagnosis	No of patients	% Of patients
Neuroendocrine	15/44	34%
Non-Hodgkin Lymphoma	13/44	29.5%
Hodgkin Lymphoma	6/44	13.6%
Pheochromocytoma	3/44	6.8%
Small cell carcinoma	3/44	6.8%
Paraganglioma	2/44	4.5%
Alveolar Rhabdomyosarcoma	1/44	2.2%
Neuroblastoma	1/44	2.2%

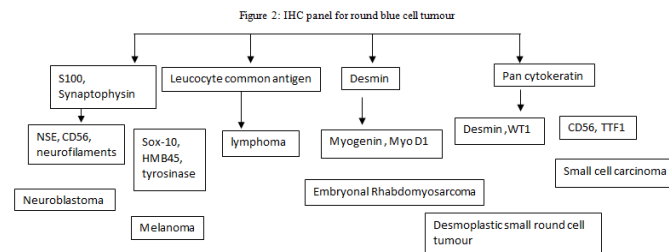
Table 2: IHC used for the diagnosis of the tumour.

Tumour name	Common IHC used
Neuroendocrine	Synaptophysin, chromogranin, Ki 67, Pan CK
Non-Hodgkin Lymphoma	CD20, CD45, Pax5, Bcl2, Bcl6, Mum1, Ki67
Hodgkin Lymphoma	CD15, CD30, Pax5, Ki67
Pheochromocytoma	Synaptophysin, Chromogranin, Ki67
Small cell carcinoma	Synaptophysin, chromogranin, Pan CK, CK7
Paraganglioma	CK, Vimentin, S100, PAS, Chromogranin
Alveolar	Desmin, Myogenin, Ki67

Rhabdomyosarcoma	
Neuroblastoma	CD56, Vimentin, Synaptophysin, Chromogranin, Ki67

Ki67 tells us the proliferating rate of the tumour. In almost all the IHC panel in our study Ki67 was used.

Figure 2: IHC panel for round blue cell tumour



### Discussion

It is very important to differentiate whether the tumour is epithelial, mesenchymal, neuroendocrine, melanocytic, and hematopoietic. To differentiate this IHC plays an important role<sup>10</sup>. IHC helps to differentiate between these tumours with specific markers like, pancytokeratin is used for epithelial tumours, desmin is used for mesenchymal tumours, leucocyte common antigen is used to see whether the origin is from lymphoid series and S100, Synaptophysin for neuronal origin.

Pancytokeratin positive will tell us the tumour is of epithelial origin, then to further differentiate if desmin comes positive then it is Desmoplastic small round cell tumour and RMS. But if desmin is negative then it will go towards carcinoma. If CD56 and TTF-1 comes positive then it is Small cell carcinoma. WT-1 is specific marker of lung tumours.

In mesenchymal tumours like Rhabdomyosarcoma Desmin along with Myogenin and Myo D1 will be positive. Leucocyte common antigen (LCA) will differentiate the lymphoma category tumours.

In neuronal tumours S100, Synaptophysin and Chromogranin are positive but S100 alone is positive in melanoma, so to differentiate further NSE, NBB4, CD56 will be positive in Neuroblastoma while Sox-10, HMB45 and Tyrosinase will be positive in Melanoma.

CD99 will be positive in both PNET/Ewings Sarcoma and B-/T-ALL. So to differentiate between them FLI-1 and NKX2.2 will be positive in PNET/Ewings Sarcoma and LCA, TdT will be positive in B-/T-ALL.

IHC plays an important role in diagnosis and confirmation of small round cell tumours

The use of extensive panels of antibodies in all malignant undifferentiated neoplasms allows accurate histological diagnosis.

Results of present study were analysed and compared with other studies.

In a comparison of the incidence of the present study, Ravi G Patel et al<sup>2</sup> out of total 75 cases showed the higher incidence of NHL 29.3% followed by EWS/PNET 18.66%, Medulloblastoma 13.33%, Rhabdomyosarcoma 9.33%, Neuroblastoma 9.33%, Retinoblastoma 8%, Wilms tumour 5.33%, Mesenchymal chondrosarcoma 4%, Hepatoblastoma 1.33%, Small cell osteosarcoma 1.33%. (Table 3)

In comparison with the study done by Amita et al of total 38 cases showed higher incidence of NHL 47.36% followed by Neuroblastoma 7.89%, Synovial Sarcoma 7.89%, Ewings Sarcoma 5.26%, Neuroendocrine Carcinoma 5.26%, Desmoplastic small round cell tumour 5.26%, Primitive Neuroectodermal Tumour 2.63%, Amelanotic melanoma 2.63%, Anaplastic Dysgerminoma 2.63%, Osteosarcoma 2.63%, Wilms Tumour 2.63%, Dendritic cell tumour testis 2.63%, Undifferentiated Nasopharyngeal Carcinoma 2.63% and Embryonal Rhabdomyosarcoma 2.63%. (Table 3)

Table 3: Comparison of incidence of Round cell tumours in present study with another study

Diagnosis	Present study	Ravi G Patel et al <sup>9</sup>	Amita et al <sup>3</sup>
Non Hodgkin Lymphoma	29.5%	26.1%	47.36%
Rhabdomyosarcoma	2.2%	7.7%	2.63%
Neuroblastoma	2.2%	5.1%	7.89%

Our study showed the most common round cell tumours are Neuroendocrine, NHL, HL followed by Pheochromocytoma, Small cell carcinoma, Paraganglioma, Alveolar Rhabdomyosarcoma and Neuroblastoma.

Majority of the round cell tumours have male predominance which was also seen in the study done by Ravi et al.

Ki 67 plays a major role. In almost all small round cell tumours in present study Ki67 index was done.

As lot of IHC is used in the diagnosis of the small round cell tumours, we should try to make a common basic panel to differentiate the tumour origin and the use specific IHC markers for further tumour categorisation.

The use of extensive panels of antibodies in all malignant undifferentiated neoplasms increases the economic burden to the patient, so tailor made IHC panel should be used along with histopathological diagnosis

This study emphasizes the role of IHC to arrive to a definite diagnosis.

**Conclusion**

Most frequent round cell tumours are Neuroendocrine, NHL, HL, Pheochromocytoma, Small cell carcinoma, Paraganglioma. The majority of the tumours have male predominance. This study emphasizes the role of immunohistochemistry to arrive at a definite diagnosis.

IHC plays an important role in treatment, diagnosis and typing of small round cell tumours. Histopathology helps in deciding the tailor made IHC panel of round cell tumour.

### **References**

1. Devoe K, Weidner N. Immunohistochemistry of small round-cell tumours. *Semin Diagn Pathol* 2000;17:216-24.
2. Philip A Pizzo, David G Poplack. Principles and practice of pediatric oncology. Chapter 30, 2010, 6<sup>th</sup> edition, 164-209.
3. Amita Patel, Role of immunohistochemistry in the differential diagnosis of malignant small round cell tumor: a study of 38 cases, December 2015, Vol 3, 3833-3839.
4. Bashyal R, Role of immunohistochemistry in the diagnosis of malignant small round cell tumors, 2011, Vol 1, 87-91.
5. Wick MR. Immunohistochemical approaches to the diagnosis of undifferentiated malignant tumors. *Annals of Diagnostic Pathology*. 2008; 72-84.
6. Arvind Rajwanshi et al. Malignant small round cell tumors. *Journal of pathology*, 2009.26(1):1-0.
7. *Semin Diagnostic pathology*, Aug 2000, Volume 17 (3): 216-224.
8. Meghavi R. Joshi, *International Journal of Current Research and Review* April 2019 Vol 11. Issue 08.
9. Ravi G Patel, *International Journal of Medical Science and Public Health* 2017, Vol 6, Issue 2.
10. Chan JK. Advances in immunohistochemistry: Impact on surgical pathology practice. *Semin Diagn Pathol* 2000;17:170-7.