

### **Orthodontic management of cleft lip and palate**

<sup>1</sup>Dr. Avkash Sakolia, Post Graduate Student, Department of Orthodontics, Desh Bhagat Dental College & Hospital, Mandi Gobindgarh

<sup>2</sup>Dr. Gurpreet Kaur, Professor, Department of Orthodontics, Desh Bhagat Dental College & Hospital, Mandi Gobindgarh

<sup>3</sup>Dr. Rajdeep Kaur, Assistant Professor, Department of Orthodontics, Desh Bhagat Dental College & Hospital, Mandi Gobindgarh

<sup>4</sup>Dr. Sanjeev Soni, Professor, Department of Orthodontics, Desh Bhagat Dental College & Hospital, Mandi Gobindgarh

<sup>5</sup>Dr. Manisha Soni, Private practitioner

**Corresponding Author:** Dr. Avkash Sakolia, Post Graduate Student, Department of Orthodontics, Desh Bhagat Dental College & Hospital, Mandi Gobindgarh

**How to citation this article:** Dr. Avkash Sakolia, Dr. Gurpreet Kaur, Dr. Rajdeep Kaur, Dr. Sanjeev Soni, Dr. Manisha Soni, “Orthodontic management of cleft lip and palate”, IJMACR- May - June - 2022, Vol – 5, Issue - 3, P. No. 224 – 231.

**Copyright:** © 2022, Dr. Avkash Sakolia, et al. This is an open access journal and article distributed under the terms of the creative commons attribution noncommercial License 4.0. Which allows others to remix, tweak, and build upon the work non-commercially, as long as appropriate credit is given and the new creations are licensed under the identical terms.

**Type of Publication:** Original Research Article

**Conflicts of Interest:** Nil

### **Abstract**

Patients with a cleft palate and or lip often require complex long-term orthodontic treatment, often in combination with a number of other specialists including maxillofacial surgery in order to produce a good facial appearance, with an esthetic, functional and stable occlusion. Team working is essential to produce successful patient outcomes. Cleft teams and their constituent clinicians are at the forefront of patient outcome assessment and any aspiring cleft team member must understand how the continuous evaluation of outcome and burden of care will further refine clinical protocols for future patients. This article will specifically introduce the role of the orthodontic consultant in the management of the cleft lip and palate patient at multiple stages of their dental development and growth. The orthodontic burden of care for these patients is high and the duration of treatment will depend on the diagnosis

and pattern of jaw growth and need for orthognathic surgery.

**Keywords:** orthodontic, cleft lip, cleft palate, management, care

### **Introduction**

Every year almost a quarter of a million new babies with cleft lip and/or palate are born in the poorest parts of the world where resources are severely limited, scarce or non-existent. In India and China alone, this may result in 2.5 million cleft lip and palate subjects for each country over a period of 50 years, assuming this is the minimum average life expectancy.<sup>1</sup>

Clefts may involve the lip, alveolus, and palate in various combinations. Half of all orofacial clefts involve both the palate and the lip. Clefts that are isolated to the palate are less common. Children born with an orofacial cleft often have complex medical and dental conditions, necessitating the need for care from healthcare teams

involving multiple specialists. Common conditions that occur in children with orofacial clefts are hearing difficulty, speech and language disorders, middle ear abnormalities, psychosocial issues, and dental abnormalities.

### **Treatment of Cleft Lip and Palate**

This correction involves surgically producing a face that does not attract attention, a vocal apparatus that permits intelligible speech and a dentition that allows optimal function and aesthetics. The cleft palate team concept has evolved from that need. Because optimal care is best achieved by multiple types of clinical expertise, the team may be composed of individual in: (1) the dental specialties (orthodontics, oral surgery, pediatric dentistry, and prosthodontics), (2) the medical specialties (genetics, otolaryngology, pediatrics, plastic surgery, and psychiatry), and (3) allied health care fields (audiology, nursing, psychology, social work, and speech pathology)

The orthodontic burden of care for patients with cleft lip and/or palate is significant as patients will often present with numerous variations and complications in their skeletal, dental and medical/behavioral presentation compared to the non-cleft patient.<sup>2</sup>

The cleft specialist orthodontist will offer care at different developmental stages and these treatments may last many months or even several years. These prolonged phases of contact with the patient and their family places the orthodontist in the position of the patient's advocate.<sup>3</sup>

The majority of patients will require orthodontic intervention at various stages extending from presurgical nasoalveolar molding as a baby to orthodontic preparation before alveolar bone grafting in the mixed dentition to alignment of the upper arch once the

permanent dentition is established. Patients may undergo a second course of orthodontic treatment on cessation of jaw growth to either camouflage an underlying skeletal discrepancy or in preparation for orthognathic surgery.

### **Treatment During Infancy**

Presurgical infant orthopedics has been used in the treatment of cleft lip and palate patients for centuries. In 1993, Grayson et al. described a new technique, nasoalveolar molding (NAM), to presurgical Ly mold the alveolus, lip, and nose in infants born with cleft lip and palate.

The initial impression of the infant with cleft lip and palate is obtained within the 1<sup>st</sup> week after birth using a heavy body silicon impression material, and the NAM appliance is inserted within the first 2 weeks. The NAM appliance has two components—the oral (molding plate) and the nasal (nasal stents). The oral component molds the clefted alveoli in order to allow them to approximate each other. The nasal components mold the distorted nasal cartilage on the clefted nose, making it more symmetrical. Nasal molding helps expand the tissue of the mucosal lining of the nose. In unilateral cleft patients, the nasal stent straightens the deviated columella toward the noncleft side. In patients with bilateral cleft lip and palate, the nasal stent elongates the deficient columella by gradually stretching the columella tissue. With the help of tape, the lips also are molded to reduce the size of the cleft. This process is done over a 3–4-month period and with active involvement by the family in the NAM process. A recent study of caregivers demonstrated that NAM was often associated with positive factors for parents such as increased empowerment, self-esteem, and bonding with their infant. After completion of NAM treatment, the infant is

then referred to the surgeon for primary closure of lip, nose, and alveolus.

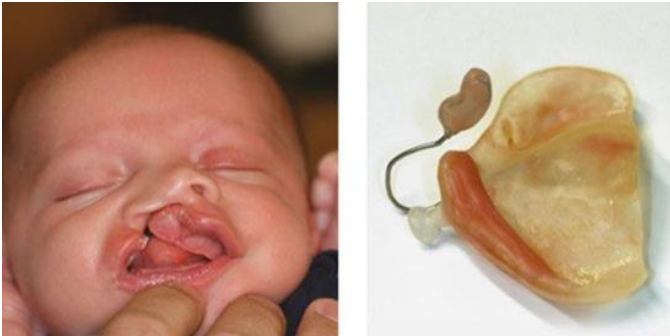

Figure 1

Between 3- and 6-months lip repair is usually carried out by the cleft surgeon. Prior to lip repair an orthodontist may be involved in a phase of oral orthopedics to align the displaced cleft segments termed presurgical orthopedic treatment. Presurgical orthopedic treatment has been used since 1950. The earlier techniques focused on elastic retraction of the premaxilla using adhesive tape binding. In 1950, McNeil introduced the use of a series of plates to actively approximate the alveolar segments into the desired position which was developed by Burst on who popularized the technique. Thereafter, Georgiade and Latham introduced a pin retained active appliance to retract the premaxilla and simultaneously expand the posterior segments over several days. Another example of an active appliance includes the DiBiase plate which uses an active coffin spring. Passive appliances aim to allow the segments to grow without the tongue being in the way. The use of passive orthopedic plates to align the cleft segments was described by Hotz in 1987 in response to controversy associated with active retraction of the premaxilla.

### Early Orthodontics

The treatment goals during the primary dentition stage of development focus on the acquisition of normal speech function, which is managed by a speech therapist or

pathologist and the surgeon. During this phase, the patient is closely monitored by the speech and language therapists. Patients may or may not need speech therapy depending on the diagnosis of speech issues. If the child has been diagnosed with velopharyngeal insufficiency, then the surgeon may perform a pharyngeal flap. This surgery is typically performed around age 2.

Another important component of care for a patient during this time period includes routine follow-up with a pediatric dentist. Regular visits to the pediatric dentist every 6 months are strongly recommended to prevent dental caries.

It is not uncommon for patients to develop a crossbite as the incisors start to erupt. If it is associated with displacement of the lower jaw, tooth wear /fremitus of the opposing dentition than an orthodontist can fabricate a simple upper removable appliance to procline the upper incisors and push them out of an anterior crossbite. Alternatively, a sectional fixed appliance can be used. Care must be taken to ensure that incisors positioned close to the cleft site are not moved out of the alveolar bone as there is typically very thin bone covering these teeth on the cleft side.

The dental development of a child with an orofacial cleft should be closely monitored as the embryological disturbance that produced the cleft will likely also have disrupted the development of the deciduous and permanent dentition and the chronology of eruption.

The cleft specialist orthodontist may be called upon for assistance to augment the care offered by the speech and language therapy team. Oral impressions for the manufacture of an electropalatographic appliance may be indicated. Electropalatographic is a technique producing a visual aid for patients having speech therapy when tongue placement needs to be improved. Multiple

electrodes are embedded in the acrylic base plate of an upper removable appliance and these are connected to a computer, which produces a live stream of tongue to palate contact images on a computer screen. The therapist and patient are then able to work together with this visual feedback to reinforce the therapy.

### **Treatment During Mixed Dentition**

The treatment objectives for a child as he/she enters mixed dentition are directed toward preparing the patient for secondary alveolar bone graft (SABG) surgery. The alveolar bone graft surgery is typically performed around 8–9 years of age. A limited volume cone-beam computed tomography (CBCT) performed at this age is invaluable to identify the cleft defect and the position of the permanent teeth adjoining the cleft defect.

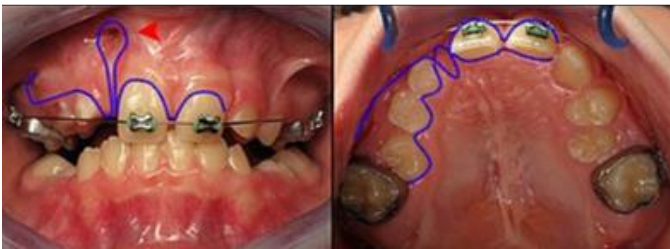

Figure 2

At this stage a patient may require an autogenous alveolar bone graft which offers a number of benefits:

1. additional bone support for unerupted teeth and teeth adjacent to the cleft which will improve their periodontal support;
  2. closure of oronasal fistulae;
  3. support and elevation of the alar base on the cleft side which will help to achieve nasal and lip symmetry;
  4. construction of a continuous arch form and alveolar ridge which in turn will allow the orthodontist to move teeth bodily and upright roots on the cleft side.
- Additionally, a more continuous archform will enable a prosthodontist/surgeon to provide a more esthetic and hygienic prosthesis when teeth are missing; and

5. stabilization and or repositioning of the premaxilla in patients with a bilateral cleft.

Most cleft patients will present with a narrow V-shaped upper arch form hence, prior to receiving an alveolar bone graft expansion of the segments that make up the upper arch form may be required by the orthodontist to improve access for surgery to allow maximum bony infill. Prior to starting active expansion an upper anterior standard occlusal radiograph, long cone periapical radiograph or CBCT of the cleft site should be considered to assess the volume of bone. Maxillary expansion prior to secondary alveolar bone grafting can be achieved by expansion which include:

1. removable appliances—these can be used to correct an anterior cross bite and simultaneously expand and correct a posterior cross bite but are less popular for cleft patients as removable appliances can impede existing speech problems;
2. rapid maxillary expansion appliances—a number of designs can be used pending the type and amount of expansion that is required. The Hyrax appliance is useful when parallel expansion is required. Fan expansion screws can be used when larger expansion is required anteriorly; and
3. a fixed quad – helix / tri - helix appliance—these appliances provide controlled force application.

The cleft surgeon and orthodontist must work in tandem to determine the anatomical limits of presurgical maxillary expansion to avoid overexpansion and development of an oronasal fistula that is beyond the limits of surgical closure. Thereafter, the arch form should be maintained with a simple upper removable appliance or trans-palatal arch. It is important to note that any primary teeth in line of the cleft should usually be removed a minimum of 3 months in advance of any

planned alveolar bone graft to allow repair of the soft tissues. Supernumerary teeth can be extracted closer to the time of alveolar bone graft.

Six months after SABG surgery, a postoperative CBCT must be obtained to confirm the outcome of SABG surgery. After successful repair of the cleft defect, the patient can then start Phase I fixed appliance treatment to correct malpositioned anterior teeth. If a patient shows a skeletal crossbite, manifested as negative overjet at this stage, protraction headgear treatment can be initiated for about 9 months to correct the skeletal crossbite.<sup>4</sup>

After alveolar bone grafting, the cleft specialist orthodontist will pay close attention to oral hygiene, local healing, the subsequent dental development and the developing and changing skeletal jaw relations of the child with an orofacial cleft.

It may be months or years following the alveolar bone graft before the teeth immediately adjacent to the cleft erupt. The lateral incisor is commonly palatally displaced from the dental arch and it is reported that the canine adjacent to the cleft may fail to erupt in up to 20% of cases.<sup>5</sup> Radiographic evaluation, often with films for parallax or cone-beam CT, may be required to assess whether or not surgical exposure and a closed eruption technique is of benefit.

In the phase immediately after alveolar bone grafting, children are often in their final years of primary school education, preparing for life at secondary school. This time often coincides with the desires of increasingly self-aware children to fit in with their peers and be of 'average appearance'. It is of benefit to those children with clefts if interceptive treatments are completed prior to this school change.

Once the success of the alveolar bone graft has been assured, the correction of rotated, tipped and angulated

incisors may be undertaken, often with fixed orthodontic appliances. In general, appliance systems with high values of maxillary arch incisor buccal crown torque and lingual crown torque in the mandibular arch are of value where compensation is required to overcome lesser class III skeletal bases. On completion of this phase of orthodontic care, the child is often still in the mixed dentition and the use of removable retention is unreliable. The employment of temporary bonded retainers is advisable and discrepancies between gingival heights will improve as the tissues mature.

Commonly, class III skeletal bases are encountered in the cleft population and the experienced orthodontic clinician will make a clinical assessment of the degree of skeletal discrepancy before determining if incisor relations and crossbites should be corrected.

Children with Pierre Robin sequence or bilateral cleft lip and palate may present with class II skeletal bases and these may lend themselves to growth modification treatment with conventional functional appliances. The temptation for prolonged, unreliable treatments involving a maxillary protraction facemask should be resisted, unless as part of the retention regime after distraction osteogenesis.

### **Treatment During Permanent Dentition**

Orthodontic treatment at this stage may be conducted to:

- relieve crowding;
- facilitate the eruption of the canine tooth with or without surgical exposure and bonding of the tooth if it has failed to erupt through the alveolar bone graft after a minimum of 6 months;
- attempt correction of a developing Skeletal III relationship;
- align the dentition;
- dental centre-line correction; and

- space closure.

Clinically, patients with clefts may present with a concave profile, midface deficiency, and a Class III skeletal pattern. The maxilla may also be deficient in transverse and vertical planes, contributing to posterior skeletal crossbite and reduced midface height. Dentally, there may be lingually inclined incisors and constricted maxillary posterior arch width, causing anterior or posterior crossbite. The extent of abnormal midface growth may vary from mild to severe.

Depending on the severity of the malocclusion presented by the cleft patient, the management can be categorized into three types. In the first category, the patients have no skeletal discrepancy and orthodontic correction is limited to tooth movement only. In the second category, there is a mild skeletal discrepancy and the patients will benefit from camouflaging the malocclusion by orthodontic tooth movement alone. In the last category of patients, there is moderate to severe skeletal deformity, and optimal results can only be obtained by combined surgical / orthodontic intervention. It is important to establish as early as possible if the patient will be treated with orthodontics alone or orthodontics in conjunction with surgery. The direction of orthodontic tooth movement to camouflage a very mild midface deficiency is opposite to that of tooth movement required to prepare a patient for midface advancement surgery.

Orthodontic preparation for the patient requiring orthognathic surgery who has a repaired alveolar cleft must take into account the previous surgical history and an evaluation of the interventions to date. A cephalometric evaluation should be recorded and assessment made. Digital two- and three- dimensional photographic and radiographic imaging should be

undertaken, supported by video, study models, recorded speech samples and psychological evaluation. Consideration should also be given to the extraction of third molar teeth. To identify patients at risk from a deterioration of their soft palate function, the effect of maxillary advancement on the velopharynx must be assessed prior to embarking upon a plan to alter the position of the maxilla. Speech assessment and video fluoroscopy are essential to fully consent a patient whose speech is at risk of becoming more nasal and this forms the basis for prediction as to whether further surgical correction of the palate may be possible.<sup>6</sup>

Where the skeletal base relationship is beyond the scope of correction by orthodontic means alone, surgical repositioning of the maxilla and/ or mandible should be considered.

#### **Patients with no skeletal deformity**

Cleft specialist orthodontists may deliberately keep the upper incisors proclined and in an anterior position, encouraging the creation of increased overjet so as to give additional support for the upper lip.

When the lateral incisor is missing, a non- extraction approach is likely to be taken in the maxilla on the cleft side in the unilateral case. Where the lateral incisor is to be substituted by the canine, modification of the shape of the canine can be undertaken and the lateral space closed. Gingival heights may need adjustment but this should be assessed when they are deemed to be mature. Where present, the diminutive lateral incisor may be moved into the arch and its dimensions improved with the addition of composite material.

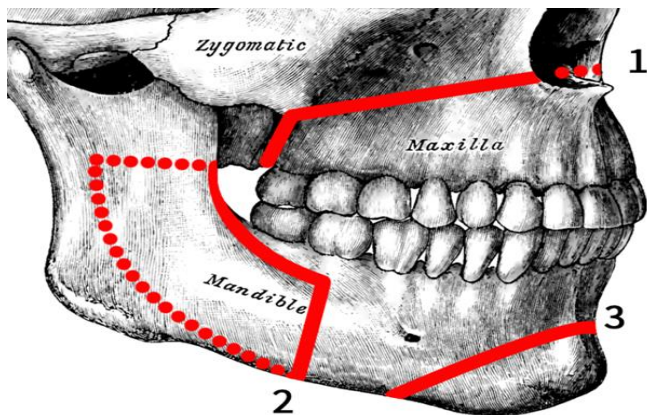
#### **Patients with mild skeletal discrepancy**

In patients presenting with mild skeletal discrepancy and minimal esthetic concern, orthodontic dental compensation may be recommended. A thorough

clinical exam, growth status and stature, hand-wrist films, and serial cephalometric assessments need to be performed before suggesting this option. However, the patient and the family should be cautioned that the outcome can be compromised if the patient outgrows the dental compensation and ultimately may need extended orthodontic treatment to remove the compensations and prepare for orthognathic surgery. Proclination of the maxillary incisors and lingual inclination of the lower incisor can adequately camouflage a mild skeletal discrepancy.

#### **Patients with moderate to severe skeletal discrepancy**

Patients presenting with moderate to severe skeletal discrepancy may achieve the best esthetic and functional results through a combination of orthodontic treatment that is carefully coordinated with orthognathic surgery. Depending on the severity of the skeletal discrepancy, the patient may require only maxillary advancement or a combination of maxillary advancement and mandibular setback. If the surgical/orthodontic option is elected, timing of the orthodontic and surgical treatment becomes critical.



It is recommended to remove all dental compensations and to align the teeth in an optimal position relative to the skeletal base and alveolar processes. The orthodontist will plan the coordination of maxillary and mandibular arch widths by hand articulating the

progressing dental study models into the predicted postsurgical occlusion. Once the presurgical orthodontic treatment goals are achieved (coordinated maxillomandibular arch width, compatibility of occlusal plans, satisfactory intercuspation), the patient may be debonded and placed on removable retainers until craniofacial skeletal growth is complete. This assessment is made by observation of the closing sutures in the hand-wrist radiographs, by measurements of mandibular body length in serial lateral cephalograms and measurements of change in stature or height. The patient is placed on fixed orthodontic appliances for a short, presurgical orthodontic treatment phase before orthognathic surgery. The combined surgical and orthodontic treatment goals are planned in close coordination with the surgeon. After the surgical correction is completed, a 12-month postsurgical orthodontic phase of treatment begins. The objectives of postsurgical orthodontics are to balance the forces of skeletal relapse with intermaxillary elastics, to observe the skeletal stability of the surgical correction, and to detail the postsurgical occlusion.

#### **Late And Retreatment Adult Orthodontics**

Adult patients often seek opinions regarding possible options for new treatments and also advice regarding revision of procedures carried out in their childhood as well as maintenance of work done years earlier. Some patients require advice only or minor interventions to achieve an optimal result whilst others require comprehensive retreatment.

If retreatment is planned, this will likely commit an adult patient to a demanding and protracted treatment plan. Serious consideration should be given both to the burden of care and the clinical risk to the tissues of a now mature individual.

Consultation with the team psychologist and the use of simulations as well as meetings and discussions with other patients will all add benefit to the decision-making process.

### **Conclusion And Summary**

This article has focused on the orthodontic aspect of cleft lip palate treatment. However, it should be noted that management is multi-disciplinary involving a number of specialists including the oral and maxillofacial surgeons, cleft surgeons, ENT surgery, restorative and pediatric dentists, plastic surgeons, psychologists and speech therapists, etc. The successful management of a patient with cleft lip and palate requires careful coordination of all members of the cleft palate team. It is important for the orthodontist to communicate well with all these specialists in the management of CLP patients to allow for timely management. Additionally, it is prudent that the parents and patient are motivated for complex and elongated orthodontic management and maintenance of a high standard of dental health throughout treatment.

### **References**

1. Michael Mars, Debbie Sell, Alex Habel. Management of Cleft Lip and Palate in the Developing World.
2. Geetanjali Sharma. Orthodontic Management of Cleft Lip and Palate Patients
3. Alexander C. Cash. Orthodontic Treatment in the Management of Cleft Lip and Palate. Cobourne MT (ed): Cleft Lip and Palate. Epidemiology, Aetiology and Treatment. Front Oral Biol. Basel, Karger, 2012, vol 16, pp 111–123
4. Shetye PR. Orthodontic management of patients with cleft lip and palate. APOS Trends Orthod 2016; 6:281-6
5. Van der Wal K, van der Meulen B: Eruption of canines through alveolar bone grafts in cleft lip and palate. Ned Tijdschr Tandheelkd 2001; 108:401–403
6. Sell D, Harding A, Grunwell P: GOS. SP.ASS.'98: an assessment for speech disorders associated with cleft palate and/or velopharyngeal dysfunction (revised). Int J Lang Common Discord 1999; 34:17–33.