

Magnetic resonance imaging evaluation of knee meniscal tears and associated lesions with arthroscopy correlation.

¹Pravallika Dasari, Senior Resident, Department of Radio-Diagnosis, Dr Pinnamaneni Siddhartha institute of medical sciences and research foundation, chinavutapalli, Gann avaram, Andhra Pradesh 521286

²Santh kumar Bellamkonda, Professor, Department of Radio-Diagnosis, Dr Pinnamaneni Siddhartha institute of medical sciences and research foundation, chinavutapalli, Gann avaram, Andhra Pradesh 521286

³Sreeja Gogula, Post graduate, Department of Radio-Diagnosis, Dr Pinnamaneni Siddhartha institute of medical sciences and research foundation, chinavutapalli, Gann avaram, Andhra Pradesh 521286

⁴Chandra Sekhar Kondragunta, HOD & Professor, Department of Radio-Diagnosis, Dr Pinnamaneni Siddhartha institute of medical sciences and research foundation, chinavutapalli, Gann avaram, Andhra Pradesh 521286

⁵Satya Chowdary Morumpudi, Post graduate, Department of Radio-Diagnosis, Dr Pinnamaneni Siddhartha institute of medical sciences and research foundation, chinavutapalli, Gann avaram, Andhra Pradesh 521286

Corresponding Author: Sreeja Gogula, Post graduate, Department of Radio-Diagnosis, Dr Pinnamaneni Siddhartha institute of medical sciences and research foundation, chinavutapalli, Gann avaram, Andhra Pradesh 521286

How to citation this article: Pravallika Dasari, Santh kumar Bellamkonda, Sreeja Gogula, Chandra Sekhar Kondragunta, Satya Chowdary Morumpudi, “Magnetic resonance imaging evaluation of knee meniscal tears and associated lesions with arthroscopy correlation”, IJMACR- March - 2023, Volume – 6, Issue - 2, P. No. 667 – 680.

Open Access Article: © 2023, Sreeja Gogula, et al. This is an open access journal and article distributed under the terms of the creative commons attribution license (<http://creativecommons.org/licenses/by/4.0>). Which allows others to remix, tweak, and build upon the work non-commercially, as long as appropriate credit is given and the new creations are licensed under the identical terms.

Type of Publication: Original Research Article

Conflicts of Interest: Nil

Abstract

MRI being the most accurate non-invasive imaging modality for diagnosing meniscal lesions allows in confirming and characterizing the meniscal lesions, identifying the type and extension of the meniscal tear and other associated indirect signs like presence of parameniscal cysts, any meniscal extrusion, and degeneration. MRI imaging has high accuracy for preoperative detection of meniscal tears, with the application of the “two-slice-touch” rule ⁽¹⁾. Diagnostic

Arthroscopy, is invasive yet accurate, and can lead to complications that may require hospital admission.

On MRI, they are classified as

- 1) horizontal tears
- 2) radial tears
- 3) longitudinal tears
- 4) oblique tears
- 5) complex tears
- 6) bucket handle tears
- 7) flap tears.

Aims: MRI evaluation of the meniscal tears with associated lesions and to correlate the findings with Arthroscopic findings.

Materials and methods: This study was carried out in the Department of Radiodiagnosis, Dr. Pinnamaneni SIMS & RF for a period of 2 years from November-2019 to October-2021.

Results: a total of 50 cases were taken. Most of the patients were seen in the age group of 15 -30 years (70%). Among the 50 patients, Isolated medial meniscal tears were seen in 52% cases, isolated lateral meniscal tears in 22% cases and both meniscal involvement in 22% cases. Most frequent type of medial meniscal tear was longitudinal tear. Most frequent types of lateral meniscal tear was longitudinal and horizontal tears. The posterior horn is the site of involvement in most of the MM & LM tears. The sensitivity, specificity, positive predictive value, negative predictive value, and diagnostic accuracy of MRI in detecting the medial meniscal tears were 94%, 80%, 91.6%, 85.7% & 90% respectively and that of lateral meniscal tears was 94.7%, 87.1%, 81.9%, 96.0% & 90% respectively. In case of concomitant ACL injury, lateral meniscus was more injured than the medial meniscus.

Conclusion: Magnetic Resonance Imaging (MRI) being a non-invasive imaging modality that has a good potential in diagnosing the knee pathologies. With MRI both the intra-articular and extra-articular pathologies of knee can be assessed, on the other hand Diagnostic Arthroscopy has certain limitations in extra-articular pathology evaluation. The inclusion of TSE (Turbo-spin-echo) sequences improves the diagnostic accuracy of MRI in particularly detecting the meniscal lesions

Keywords: long itudinal meniscal tear; horizontal meniscal tear; radial meniscal tear; medial meniscus (mm) lateral meniscua (lm); mri knee; diagnostic arthroscopy.

Introduction

In assessing the pathologies of knee joint, the potential of MRI was first described by Kean and Moon in 1983. MRI has a high reliability in detecting and diagnosing the pathologies or injuries of the knee intraarticular structures like menisci and cruciate ligaments when compared with arthroscopy, which is still considered as gold standard. MRI allows in confirming and characterizing the meniscal lesions, identifying the type and extension of the meniscal tear and other associated indirect signs like presence of parameniscal cysts, any meniscal extrusion, and degeneration.

The menisci are C-shaped fibro cartilagenous or semilunar cartilages that are firmly attached to the tibial condylar surface which provide added mechanical stability for the knee joint, protect the articular cartilage, provide joint lubrication. They are triangular in cross-section where the apex points towards the intercondylar notch and with any outer convex curve. Each meniscus is divided into three geographical zones from anterior to posterior: anterior horn, body, and posterior horn. The anterior horns of the MM and LM are connected by fibrous band tissue called the transverse or intermeniscal ligament ^(2,3).

The normal meniscus shows homogenously low intensity signal on all MRI sequences i.e. T1W, Proton Density, T2W (conventional and FSE), Gradient Echo, and STIR-weighted images. In adults, the peripheral 1/3rd of the meniscus often shows high signal intensity due to normal vascularity ⁽⁴⁾.MM is more firmly attached to the capsule throughout its periphery and has less

mobility than the lateral meniscus, so tears are more common in the medial meniscus. Younger patients (under 30 years old) have a higher incidence of lateral meniscal tears due to sporting events than older individuals. This is most likely due to the greater prevalence of simultaneous ACL rupture in this group.

Classification of meniscal tears: (Fig 1,2)

MRI imaging has high accuracy for preoperative detection of meniscal tears, with the application of the “two-slice-touch” rule. Meniscal tears occur on two main planes: vertical and horizontal.

Horizontal tears

They are usually parallel in orientation to the tibial plateau dividing meniscus as superior and inferior segments. (Fig 15;16).

Vertical/ longitudinal tears

The vertical tears are parallel to the meniscal long axis and are oriented perpendicular to the tibial plateau. These tears can be oriented obliquely too. (Fig 17).

Root tears

They are full-thickness radial tears that usually involve the meniscotibial attachment of the posterior horn and meniscal root.

Bucket-handle tears

The bucket-handle tear represent a displaced longitudinal tear and usually occur in medial meniscus. In this type of tears, the displaced central fragment appears as a handle of the bucket, the undisplaced large peripheral fragment is usually attached to the tibial surface represents a bucket. The bucket-handle tears occur in young population in setting of trauma. (Fig 18).

Flap tears

It is considered as a pattern of horizontal and oblique tears which usually begins in the meniscal free edge with

displacement of fragments into the intercondylar notch or the medial or lateral parameniscal recesses ⁽⁵⁾.

Complex tears

They either comprise two or more tear configurations or are difficult to define into a definite tear type.

❖ Other associated indirect signs of meniscal tear include: presence of parameniscal cysts, any meniscal extrusion, and degeneration.

Diagnostic criteria

Meniscal tear on MRI can be diagnosed when there is

- a) Intermediate or high signal intensity intrasubstance area with or without extension to articular surface.
- b) Abnormal morphology of the menisci

Aims and objectives

The aim of this study is MRI evaluation of the meniscal tears with associated lesions and to correlate the findings with Arthroscopic findings.

The objective of this study is

- To identify the MRI appearances and various patterns of the meniscal lesions in both traumatic and non-traumatic knee joints.
- To identify the Grade & Extension of meniscal lesions; Meniscal extrusion; Meniscal cyst.
- To correlate these findings with arthroscopic findings.

Materials and methods

This study was carried out in the Department of Radiodiagnosis, Dr. Pinnamaneni SIMS & RF, Gannavaram, Andhra Pradesh.

Population and study subjects

Inclusion criteria

- Patients of age group 15-75 years with complain of pain in the knee joint/joints, with or without a history of trauma.

Exclusion criteria

- **Patients who are non-compliant to MRI.**
- Patients who have not undergone arthroscopy were excluded.

Mode of selection of subjects

- Patients of 15 - 75 years of age groups

Equipment, materials used

The images were obtained using 1.5 Tesla Philips Achieva d-stream MRI machine in the Radio diagnosis department. The MRI findings were correlated with Arthroscopy Findings for the detection of false-positive and false negative results of preoperative MR images. The presence or absence of a tear, fraying, and degeneration were noted for both menisci

Technique used

PD SPAIR axial, coronal & sagittal; PD TSE coronal; T2 sagittal & coronal; T2 FFE; T1 sagittal.

Statistical analysis

Data was loaded in Microsoft-Excel to be analyzed by using SPSS software. Frequencies and percentages were used to represent descriptive statistics. The sensitivity, specificity, positive predictive value and negative predictive values, and diagnostic accuracy of the MRI findings and Arthroscopy findings were calculated to assess the reliability of MRI results.

Observations and results

Knee joints of a total of 50 patients were examined. Maximum patients i.e, 35 were in 15-30 years age group and minimum patients i.e, 3 in >45 years age group (Table/ figure 3). Out of 50 cases 43 were males and 7 were females (Table & Graph 4). Among the study 26 patients have isolated MM tear, 11 have isolated LM tear and 11 have both MM & LM tears. (Table & Graph 5). Among the MM tears, Longitudinal tears are more common i.e, 8 patients; followed by RADIAL &

Horizontal tears and posterior horn is the most common site of involvement (Table & Graph 6,7). Among the LM tears, Longitudinal & Horizontal tears are most commonly seen i.e, 6 patients each and posterior horn is the most common site of involvement (Table & Graph 8,9).

The sensitivity, specificity, positive predictive value, negative predictive value, and diagnostic accuracy of MRI in detecting the medial meniscal tears were 94%, 80%, 91.6%, 85.7% & 90% respectively (Table & Graph 10) and that of lateral meniscal tears were 94.7%, 87.1%, 81.9%, 96.0% & 90% respectively (Table & Graph 11).

Among 50 patients, 38 patients showed joint effusion as secondary sign associated with meniscal tear. Complete tear of ACL is associated with meniscal tear in 25 patients and PCL buckling is associated with meniscal tear in 13 patients.

Discussion

Mechanism of meniscal tear

The meniscal injury occurs when there is a femoral rotation against the affixed tibia during the flexion and extension of the knee. Hence movements such as twisting forces, squatting, shearing forces causing compression at the knee are all associated with damage of the menisci ⁽⁶⁾.

Radiological parameters

grades of meniscal tears and degeneration [7] [8] [9] [10]

- Grade 1: Focal, globular and non-articular intra substance increase in signal intensity (Fig.12).
- Grade 2: Horizontal intrameniscal high signal intensity that often extends from the meniscal capsular periphery without any involvement of the capsule (Fig.13).

The grade 2 signals are categorised into:

- Type 2A: It is a linear signal without involving articular surface.
- Type 2B: It is an abnormal signal intensity which comes in contact with one of the articular surfaces on a single MR image.
- Type 2C: is a very extensive signal however, does not demonstrate any contact with articular surface.
- Grade 3: higher signal intensity in the meniscus that spans over a considerable portion of the meniscus and communicates with at least one of the meniscal articular surfaces (Fig.14).
- Grade 4: It is used to describe a complex tear with several components or fragments.
- Grade 1 and 2 lesions do not imply a tear, but rather mucinous and mucoid intrasubstance degeneration, and are most commonly seen in the third or fourth decade [9].

Abnormal meniscal morphology

Meniscal morphological changes which are associated with meniscal tears include:

- the tip of the inner free meniscal edges appear blunted,
- displacement of a meniscal portion,
- interrupted or disrupted appearance of the meniscus,
- and unusual size of a detached segment of meniscus (a bucket handle tear) with small but very often truncated residual peripheral portion.

This displaced portion is frequently found beneath the PCL in the intercondylar notch. Coronal views can aid in the identification of displaced fragments. The "notch" sign, which is an abrupt variation in the contour of the meniscus, is a significant predictor of a meniscal tear. The presence of an abnormal intradiscal signal makes the notch sign a more definitive predictor of a meniscal tear than the usual meniscal flounce [11].

Meniscal CYST

It occurs when the joint synovial fluid escapes into the meniscal tears and hence seen as a fluid filled cyst which has T1W intermediate signal intensity and T2W hyper intensity adjacent to a meniscus. These are also termed as ganglion cysts. These cysts can often has lobulations or septations. They show a strong association with a cleavage type horizontal tear.

Menisocapsular separation

The meniscal detachment from its capsular attachment is termed as Menisocapsular separation and usually occur concomitant with other injuries. It is more frequent medially. Menisocapsular detachment is best predicted by the presence of peri meniscal fluid and an irregular meniscal border.

In an earlier study done by Krati Khendelwal in 210 study population, 161 (76.2%) were males and 49 (23.8%) were females. The majority of the patients were observed in the 21-30 years age group contributing to 47.14% [13]. The majority of the patients in this study were in between the age from 15 years to 30 years (70%). The patients from 31 to 45 years were 24% and above 45 years were 6% only. The observations in our study showed a predilection of knee meniscal injuries in males and the young age group. These observations were in accordance with other several studies which favour young male predilection [12][14][15].

The medial meniscal tears are seen more frequently than the lateral meniscal tears. In this study, it was assessed that 72% of cases showed isolated medial meniscal tears and isolated lateral meniscal tears were seen in 22% cases. About 22% cases showed involvement of both the medial and lateral menisci. In a study by Drosos et.al in a study population of 392 patients, the percentage of medial meniscal tears (70.7%) was more than the lateral

meniscus. Also, a small percentage of patients about 5.9% had tears involving both the medial and lateral menisci [16]. Similar findings were also observed in our study.

Medial meniscus tears

In our study, most of the medial meniscal tears were detected in the posterior horn (72.2%) followed by combined body and posterior horn involvement in 19.4% of cases. A previous study was done by Gupta et al. which included a study population of 50 patients observed that the posterior and body of the medial meniscus were involved in 10 out of 18 cases of medial meniscal tears. [17]

In an earlier study done by Krati Khendelwal in 210 study population, out of the 95 cases having grade III tear in MM, longitudinal tears were seen in 38 cases (40%), followed by horizontal tears in 16 cases (16.84%), radial tears in 14 cases (14.7%), bucket handle in 13 cases (13.6%), complex tears in 8 cases (8.4%) and flap tears in 6 cases (6.3%) [13]. The distribution of tears in this study were in correlation with our present study.

The sensitivity, specificity, positive predictive value, negative predictive value, and diagnostic accuracy of MRI in detecting the medial meniscal tears were 94%, 80%, 91.6%, 85.7% & 90% respectively in the present study. In studies done by Bari et.al. and Kulkarni et.al. correlated 71 & 100 MRI cases each with Arthroscopy and concluded that the sensitivity, specificity, positive predictive value, and negative predictive value of MRI in detecting the medial meniscal tears were 93.5%, 87.50%, 85.29%, 94.9% and 86%, 85%, 89.6%, 80.9%, 86% respectively [18,19].

Krati Khendelwal et.al in a study population of 210 patients, concluded the Sensitivity, specificity, accuracy, positive predictive value, and negative predictive value

of MRI grade III tears (95 cases) compared to Arthroscopy were 95.69%, 94.87%, 95.23%, 93.68%, and 96.52%. [13] However, the present study showed lower specificity and negative predictive values.

In a meta-analysis done by Oei et al which included 120 retrieved articles, the pooled weighted sensitivity and pooled weighted specificity of MRI in detecting medial meniscal tears was calculated to be 93.3% and 88.4% respectively. The present study showed a nearly similar observation of sensitivity of 94% and lower specificity of 80%. [20]

Lateral meniscus tears

In this study, the posterior horn was the site of involvement in 11 cases (50%) followed by body and anterior horn involvement each in 18.2% of cases. The combined posterior horn and body tears were observed in 3 cases each (13.6%).

In an earlier study done by Krati Khendelwal in 210 study population, out of the 42 cases having grade III tear in LM, longitudinal tears were seen in 16 cases (38.10%), followed by horizontal tears in 9 cases (21.43%), radial tears in 10 cases (23.81%), complex tears in 3 cases (8.4%) bucket handle in 2 cases (4.76%), and flap tears in 2 cases (4.76%) [13]. The distribution of tears in our present study was in correlation with the above study.

The sensitivity, specificity, positive predictive value, negative predictive value, and diagnostic accuracy of MRI in detecting the lateral meniscal tears was 94.7%, 87.1%, 81.9%, 96.0% & 90% respectively. A study by Bari et.al. correlated 71 MRI cases with Arthroscopy and concluded that the sensitivity, specificity, positive predictive value, and negative predictive value of MRI in diagnosing the lateral meniscal tears was 77.7%, 81.8%, 72.4%, and 85.71% respectively [18]. This present study

showed better values of sensitivity and positive predictive values compared to the study by Bari et al. In study done by Kulkarni et.al. who correlated 100 MRI cases with Arthroscopy the sensitivity, specificity, positive predictive value, negative predictive value, and diagnostic accuracy of MRI in detecting the lateral meniscal tears was 73.3%, 87.19%, 70.96%, 88.41% & 83% respectively. Our study showed higher sensitivity and positive predictive values ^[19]. The diagnostic accuracy in the present study was 90%.

In a meta-analysis done by Oei et al which included 120 retrieved articles, the pooled weighted sensitivity and pooled weighted specificity of MRI in diagnosing lateral meniscal tears was calculated to be 79.3% and 95.7% respectively. The present study showed a higher sensitivity of 94.7% and lower specificity of 87.1%.^[20]

Associated ligamentous pathologies

Of the 50 cases included in this study, 42 cases showed tears on ACL constituting 84%. The rest of the 16% cases i.e. 8 cases did not show any ACL pathology. Of the 42 cases with ACL pathology, 25 cases showed complete/total tear (25%), It was also observed that 10 cases of 42 ACL tears were in association with lateral meniscal tears and 12 cases of 42 ACL tears were in association with tears in both the menisci.

In several previous studies, it was assessed that there was a decrease in the sensitivity of MRI from 86%-96% to 84%-88% in detecting the medial meniscal tear in the ACL-deficient knee. In the case of lateral compartment involvement, a further drop in the sensitivity was observed from 84%-94% to 68%-83%. There was a severe decrease in sensitivity in the case of multiple torn knee ligaments: 57% for medial and 78% for lateral meniscal tears.^{[21][22][23]}

Secondary signs

Joint effusion

In our study, joint effusion was observed in 38 cases accounting for 76%. In study by Gul-e-Khanda which included a study population of 50 patients observed that 43 patients (86%) had joint effusion, bone edema, or bone bruise was observed in 17 cases that accounted for 34%.^[24]

Subchondral bone edema

Subchondral bone edema was usually found immediately adjacent to the meniscus. In our present study, subchondral bone edema was observed in 10 cases accounting for 20%.

This sign can be observed in more than 60% of MM tears and more than 90% of LM tears, with a sensitivity and specificity of 64%–70% and 94%–100% for the MM, respectively, and 88%–89% and 98%–100% for the LM, respectively.

Bone contusions

In our present study, bone contusions were observed in 17 cases (34%). Also, Kaplan et.al in his study with a study population of 215 patients concluded that medial tibial bony contusions were associated with MM tears with posterior horn involvement in 64% cases and associated with only 36% cases.^[25]

Meniscal extrusion

In our present study, it was detected that 18% of cases i.e., 9 cases were associated with meniscal extrusion. Of which, extrusion with MM tears was seen in 6 cases, whereas extrusion with LM tears was observed in 3 cases. In our study, all the 6 cases with MM tears in association with extrusion were seen involving the posterior horn and both the posterior horn and body. These observations were similar to the previous studies done by Choi et.al.^[26]

Parameniscal cysts

Medial parameniscal cysts are usually symptomatic. Parameniscal cysts are associated more with LM tears rather than MM tears. [12] In this present study, parameniscal cysts were found in 5 cases accounting for 10%. Out of these 5 cases, parameniscal cysts were associated with lateral meniscal tears in 3 cases and with medial meniscal tears in 2 cases. A study by Bergin et. al regarding the indirect soft-tissue and osseous signs of MRI in proven meniscal tears concluded that, presence of parameniscal and intrameniscal cysts as an indirect sign of meniscal tears with 100% specificity and 100% positive predictive value. [21] A study by DeSmet et.al observed that 28 cases with parameniscal cysts over the body or posterior horn had underlying tears which showed 100% association whereas only 96% of MM tear cases were associated with the parameniscal cysts. [27]

Meniscal degeneration

Degenerative tears, which arise as a result of age-related stress, account for up to 30% of all the meniscal tears. Such degenerative tears can occur with or without trauma. The male population of age group 40-60 years is usually associated with meniscal degeneration-related tears. A study by Meltem et.al with a population of 306 patients who were in the age between 65 years to 89 years, observed that there is a fairly high prevalence of damage to the menisci in elderly population and concluded that meniscal damage or degeneration was observed in elderly population with knee osteoarthritis. [28]

Conclusion

Magnetic Resonance Imaging (MRI) is less time consuming, and safe method for the evaluation of the meniscal lesions and surrounding anatomy in contrast to the diagnostic Arthroscopy. When there is a clinical

suspicion of meniscal injury or any pathology, prior performance of MRI prevents the unnecessary Arthroscopies which has certain complications and require hospitalization. MRI can aid for the pre-operative assessment for planning the Arthroscopy, to know the prognosis, early diagnosis and severity of the injuries when it involves more than one intra-articular structures of knee. With MRI both the intra-articular and extra-articular pathologies of knee can be assessed, on the other hand Diagnostic Arthroscopy has certain limitations in extra-articular pathology evaluation. The MRI along with clinical assessment can be a reliable tool for the evaluation of the meniscal pathologies, particularly in cases of complex or multiple knee injuries. However, MRI has certain pitfalls in diagnosing the radial tears and root tears, displaced fragments and Menisocapsular separation. The MRI has high accuracy in detecting the meniscal tears pre-operatively by applying the “two-slice-touch” rule. With a good knowledge of the normal anatomy, anatomic variants and certain indirect signs of meniscal tears diagnostic errors can be minimized. The inclusion of TSE (Turbo-spin-echo) sequences improves the diagnostic accuracy of MRI in particularly detecting the meniscal lesions.

References

1. Nguyen, J. C., et al., MR Imaging-based Diagnosis and Classification of Meniscal Tears Radio Graphics, 2014;34(4):981–999.
2. Johnson DL, Swelson T, Livesay GA, et al. Insertion-site anatomy of the human menisci: gross, arthroscopic and topographical anatomy as a basis for meniscal transplantation. *Arthroscopy* 1995; 11:386.
3. Warren RF, Arnoczky SP, Wickiewicz TL. Anatomy of the knee. In: Nicholas JA, Hershman EB,

eds. *The Lower Extremity and Spine in Sports Medicine*. St. Louis: Mosby; 1986:657-694

4. Matthew H. Blake, MD, Christian Lattermann, MD, and Darren L. Johnson, MD. MRI and Arthroscopic Evaluation of Meniscal Injuries. *Sports Med Arthrosc Rev* 2017; 25:219–226.

5. Lecouvet FE, Malghem J, Maldague BE, Vande Berg BC. MR imaging of epiphyseal lesions of the knee: current concepts, challenges, and controversies. *Radiol Clin North Am* 2005; 43:655—72

6. Cannon WD, Morgan CD. Meniscal repair: II. Arthroscopic repair techniques. *J Bone Joint Surg [Am]* 1994; 76:294.

7. Stoller DW. Meniscal tears: pathological correlation with MR imaging. *Radiology* 1987;163: 452.

8. Crues JV, Stoller DW. The menisci. In: Mink JH, Reicher MA, Crues JV, et al, eds. *MRI of the knee*. New York: Raven Press, 1993(2):91-140.

9. Romulo Balthazar, Calvin Ma, Steven Shankman, Javier Beltran. *The Knee*. In: John R Haga, Vikram S Dogra, Michael Forsting, Robert C Gilkeson, Hyun Kwon Ha, Murali Sundaram, editor. *CT and MRI of the whole Body*. 5th edition. Philadelphia: Elsevier Mosby, 2009:2317-2368.

10. Costa CR, Morrison WB, Carrino JA. Medial Meniscus extrusion on knee MRI: Its extent associated with severity of degeneration or type of tear *AJR Am J Roentgenol* 2004;183(1):17–23.

11. Bruno C. Vande Berg, Jacques Malghem, Pascal Poilvache, Baudouin Maldague, Frédéric E. Lecouvet. Meniscal Tears with Fragments Displaced in Notch and Recesses of Knee: MR Imaging with Arthroscopic Comparison. *Radiology* 2005; 234:842–850.

12. Ochoa LM, Dawson L, Patzkowski JC, Hsu JR. Radio graphic prevalence of femoroacetabular impinge

ment in a young population with hip complaints is high. *Clin Orthop Relat Res* 2010 468:2710– 2714

13. Thornton DD, Rubin DA. Magnetic resonance imaging of the knee menisci. *Semin Roentgenol* 2000; 35:217–30.

14. Krati K, V.C. Chaturvedi, Vineet Mishra, Gaurav K. Diagnostic accuracy of MRI knee in reference to arthroscopy in meniscal and anterior cruciate ligament injuries. *The Egyptian Journal of Radiology and Nuclear Medicine*, 2018;49: 138–145.

15. Ahmad M, Ayub Z, Hadi N. Prevalence of various types of intra-articular injuries detected by Magnetic resonance imaging in trauma to the knee joint. *J Med Sci* 2005; 13:136–9.

16. Drosos GI, Pozo JL. The causes and mechanisms of meniscal injuries in the sporting and non-sporting environment in an unselected population. *Knee* 2004; 11 (2):143–9.

17. Gupta K, Guleria M, Sandhu P, Galhotra R, Goyal A. Clinico-radiological correlation in the diagnosis of ligament and meniscus injuries at knee joint: A prospective study. *Saudi J Sports Med* 2013; 13:22-6.

18. Bari AA, Kashikar SV, Lakhkar BN, Ahsan MS. Evaluation of MRI versus arthroscopy in anterior cruciate ligament and meniscal injuries. *J Clin Diagnostic Res*. 2014 Dec;8(12):14-18

19. Kulkarni OP, Pundkar GN, Sonar SB. A comparative study of MRI versus arthroscopic findings in ACL and meniscal injuries of the knee. *Int J Res Orthop* 2018; 4:198-202.

20. Edwin H. G. Oei, Jeroen J. Nikken, Antonia C.M. Ver Stijnen, Abida Z. Ginai, M.G. Myriam Hunink, MR Imaging of the Menisci and Cruciate Ligaments: A Systematic Review. *Radiology* 2003; 226:837–848.

21. De Smet AA, Graf BK: Meniscal tears missed on MR imaging: Relationship to meniscal tear patterns and anterior cruciate ligament tears. AJR Am J Roentgenol 1994; 162:905.
22. Fischer SP, Fox JM, Del Pizzo W, et al: Accuracy of diagnosis from magnetic resonance imaging of the knee: A multi-center analysis of one thousand and fourteen patients. J Bone Joint Surg 1991;73A:2
23. Rubin DA, Kettering JM, Towers JD, et al: MR imaging of knees having isolated and combined ligament injuries. AIR Am J Roentgenol 1998; 170:1207.
24. Khanda GE, Akhtar W, Ahsan H, Ahmad N. Assessment of menisci and ligamentous injuries of the knee on magnetic resonance imaging: correlation with arthroscopy. J Pak Med Assoc. 2008 Oct;58(10):537-40.
25. Kaplan PA, Gehl RH, Dussault RG, Anderson MW, Diduch DR. Bone contusions of the posterior lip of the medial tibial plateau (contrecoup injury) and associated internal derangements of the knee at MR imaging. Radiology 1999;211(3):747-753.
26. Choi CJ, Choi YJ, Lee JJ, Choi CH. Magnetic resonance imaging evidence of meniscal extrusion in medial meniscus posterior root tear. Arthroscopy 2010; 26 (12):1602-1606
27. Singson RD. MR imaging of displaced bucket-handle tear of the medial meniscus. AJR Am J Roentgenol 1991; 156:121.
28. Meltem O et al, Meniscal lesions in geriatric population prevalence and association with knee osteoarthritis. Current Aging Science, 2019;12(1): 67-73.
29. F. Lecouvet T. Van Haver et al, Magnetic resonance imaging (MRI) of the knee: Identification of difficult-to-diagnose meniscal lesions. Diagnostic and Interventional Imaging 2018; 99:55-64.

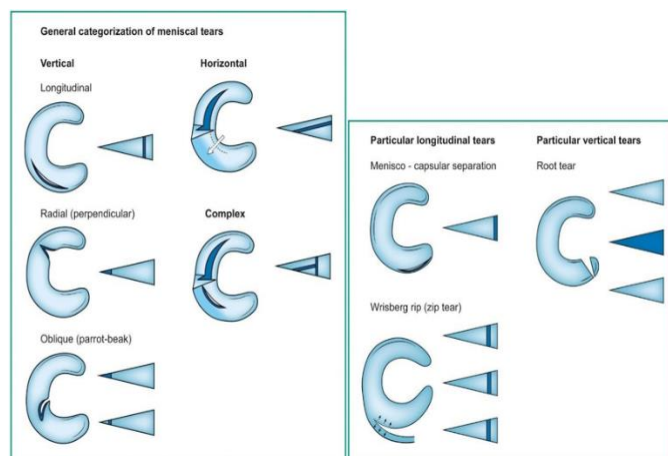


Figure 1: types of meniscal tears [29]

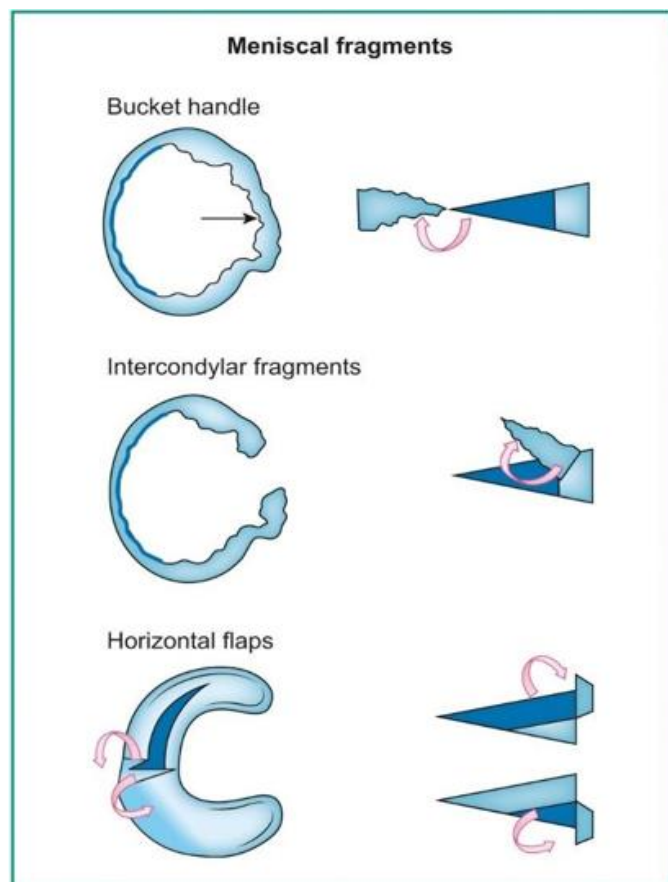


Figure 2: bucket handle & flap tears [29]

Table 3: age distribution.

Age group (years)	No. Of patients	Percentage
15- 30	35	70.0%
31-45	12	24.0%
>45	3	6.0%

Graph 3: age distribution.

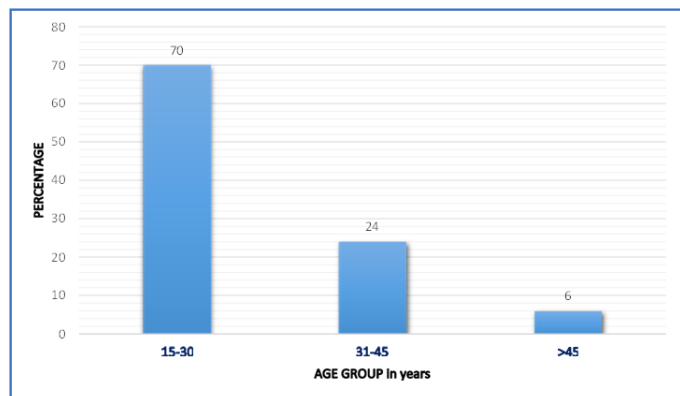


Table 4: sex distribution

Sex	No. Of patients	Percentage
Male	43	86%
Female	07	14%
Total	50	100%

Graph 4: sex distribution

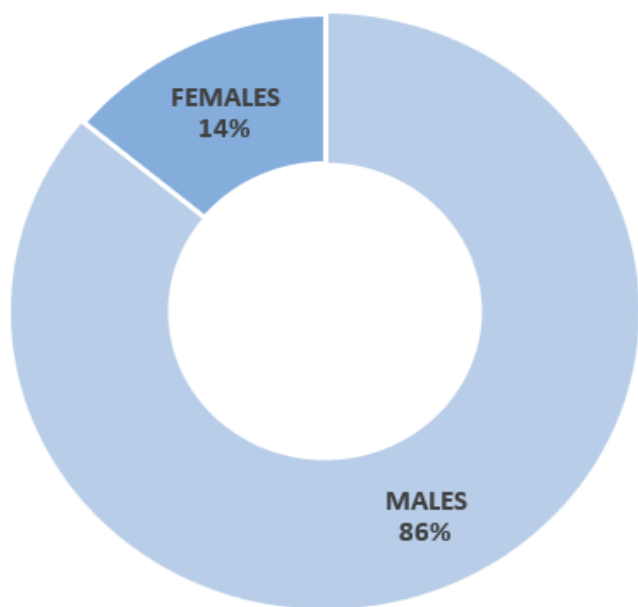


Table 5: percentage distribution of meniscal tears in MRI

Tears	No. of patients	Percentage
Isolated medialmeniscal tears	26	52%
Isolated lateralmeniscal tears	11	22%
Both	11	22%

Graph 5: percentage distribution of meniscal tears in MRI

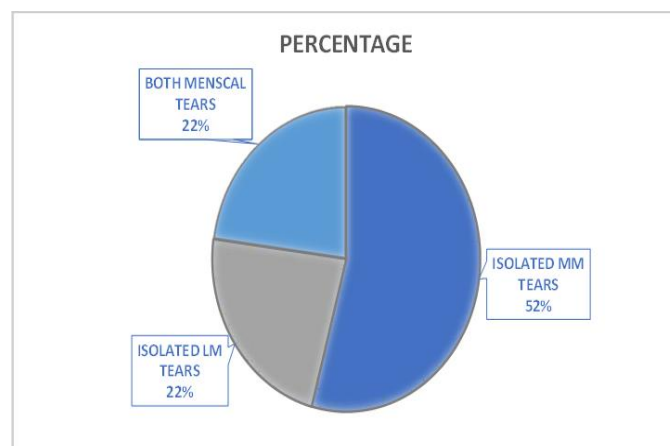


Table 6: percentage distribution of type of medial meniscal tears.

Type of mm tears	No. Of patients	Percentage
Longitudinal	8	22.2%
Radial	7	19.4%
Oblique	5	13.8%
Horizontal	7	19.4%
Complex	3	8.3%
Bucket handle	5	13.8%
Flap tear	1	2.7%
Total	36	100%

Graph 6: percentage distribution of type of medial meniscal tears

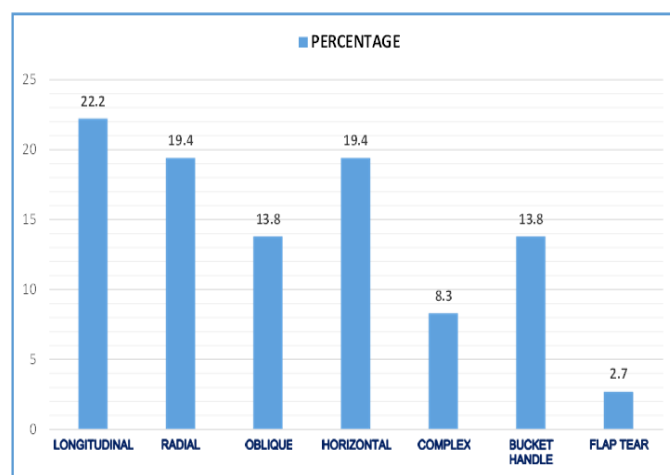


Table 7: Distribution of medial meniscal tears according to the site of involvement

Site of involvement	No. Of patients	Percentage
Posterior horn	26	72.2%
Anterior horn	01	2.8%
Body	01	2.8%
Root	01	2.8%
Posterior horn and body	07	19.4%
Total	36	100%

Graph 7: distribution of medial meniscal tears according to the site of involvement

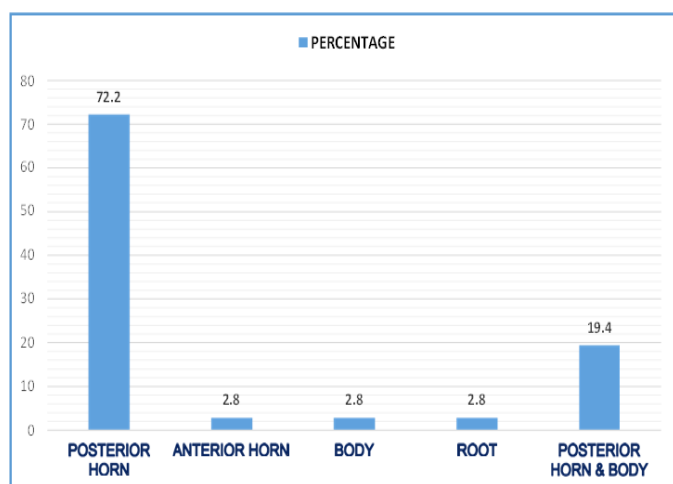


Table 8: percentage distribution of type of lateral meniscal tears

Type of lm tears	No. Of patients	Percentage
Longitudinal	6	27.3%
Radial	3	13.6%
Oblique	3	13.6%
Horizontal	6	27.3%
Complex	2	9.1%
Bucket handle	2	9.1%
Flap tear	0	0%
Total	22	100%

Graph 8: percentage distribution of type of lateral meniscal tears

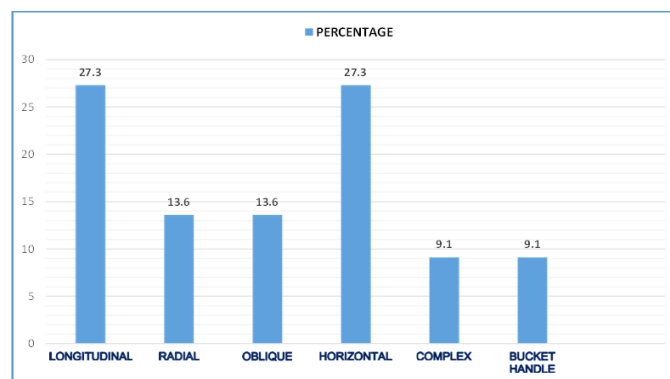


Table 9: distribution of lateral meniscal tears according to the site of involvement

Site of involvement	No. Of patients	Percentage
Posterior horn	11	50.0%
Anterior horn	04	18.2%
Body	04	18.2%
Root	0	0%
Posterior horn and body	03	13.6%
Total	22	100%

Graph 9: distribution of lateral meniscal tears according to the site of involvement

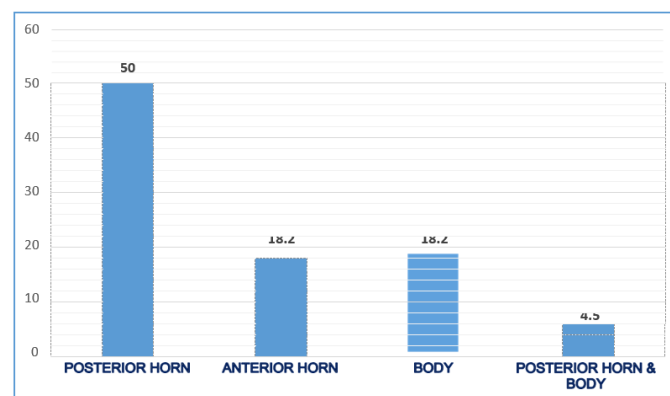


Table 10: sensitivity, specificity, ppv, npv & diagnostic accuracy of mri in medial meniscal tears Detection

MRI	Arthroscopy		
	Positive	Negative	
Positive	33	3	36
Negative	2	12	14

Total	35	15	50
	50		

Graph 10: sensitivity, specificity, ppv, npv & diagnostic accuracy of mri in medial meniscal tears detection.

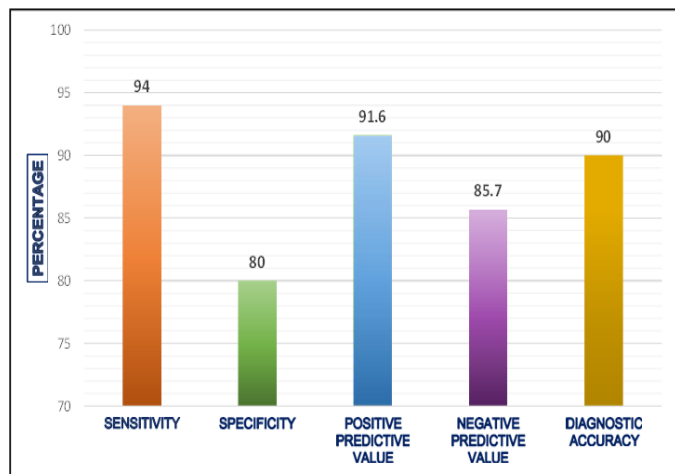


Table 11: sensitivity, specificity, ppv, npv & diagnostic accuracy of mri in lateral meniscal tears detection

MRI	Arthroscopy		
	Positive	Negative	
Positive	18	4	22
Negative	1	27	28
TOTAL	19	31	50
	50		50

Graph 11: sensitivity, specificity, ppv, npv & diagnostic accuracy of mri in lateral meniscal tears detection

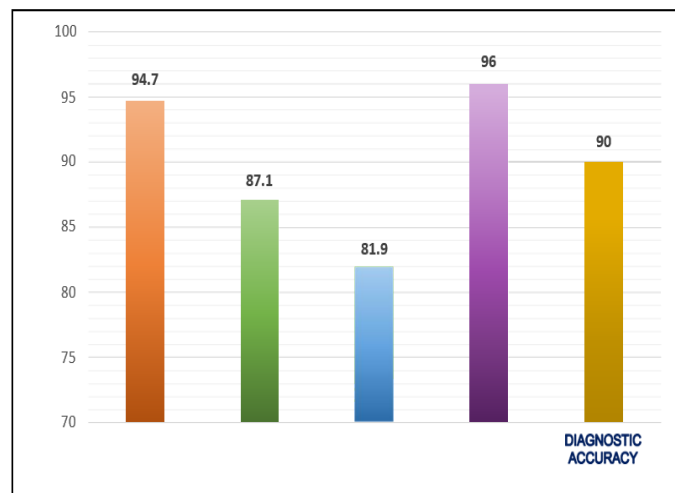


Figure 1: coronal and sagittal mr images showing grade 1 meniscal abnormality

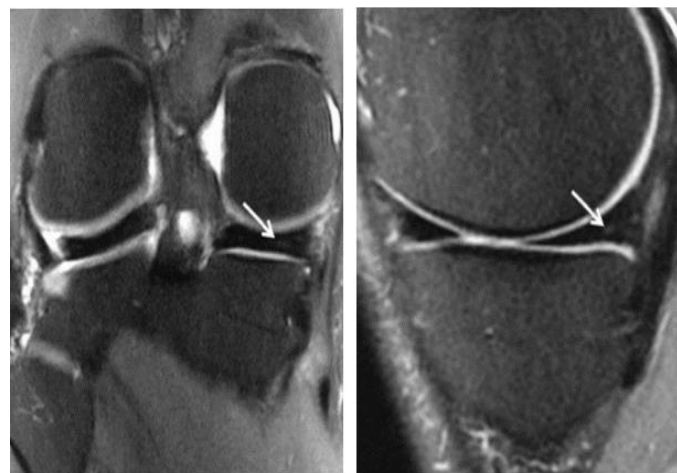

Figure 2: coronal and sagittal mr images showing grade 2 meniscal abnormality.

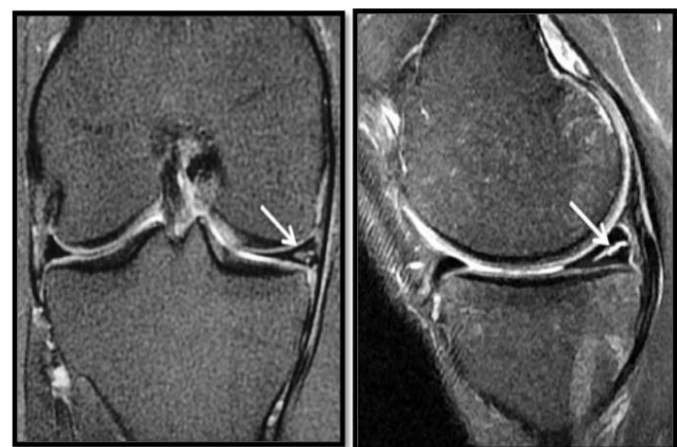

Figure 3: coronal and sagittal mr images showing grade 3 meniscal abnormality.

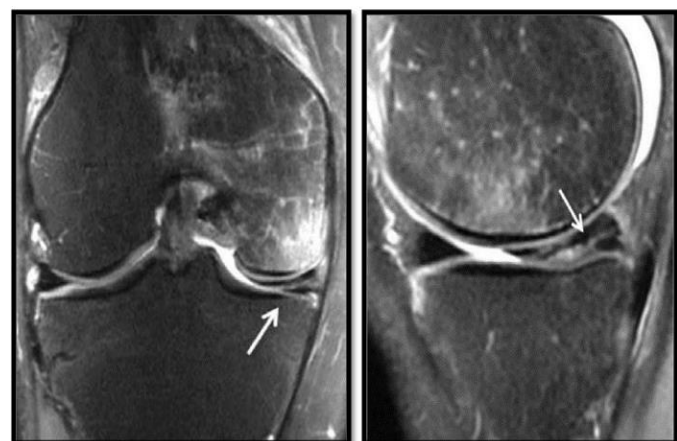


Figure 4: horizontal tear in the posterior horn of medial meniscus.

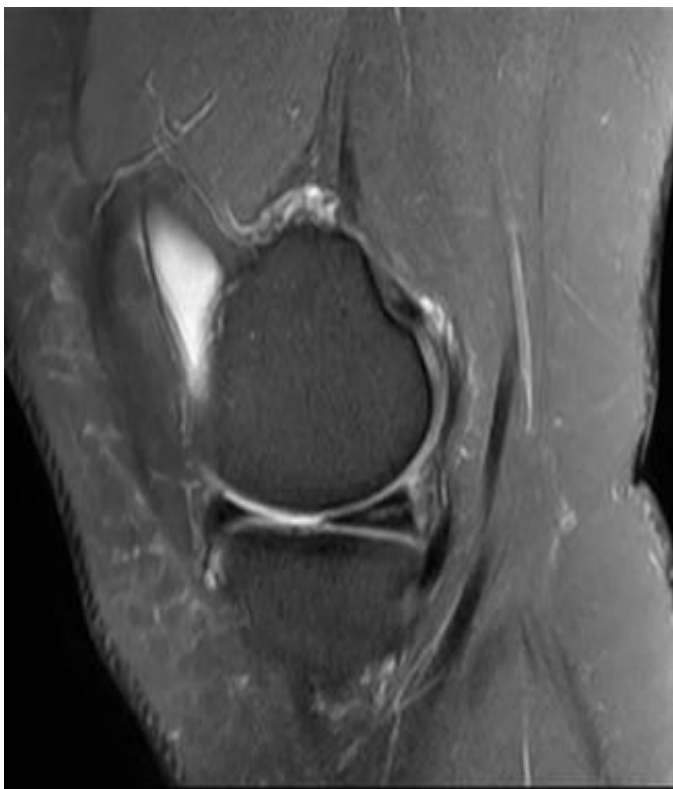


Figure 6: sagittal pd image showing longitudinal tear in the posterior horn of mm.

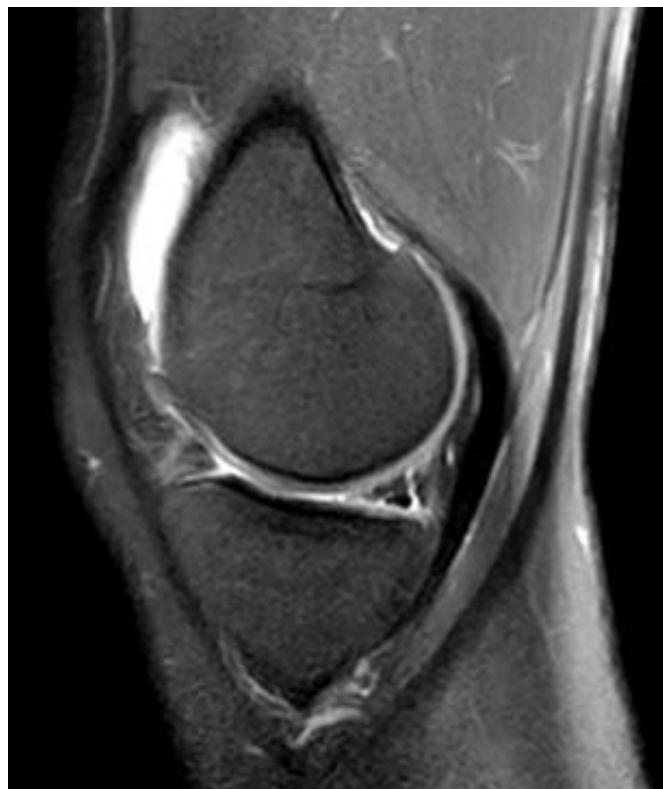

Figure 5: sagittal pd spir image showing horizontal tear in the posterior horn of lm. Suprapatellar bursal fluid seen.

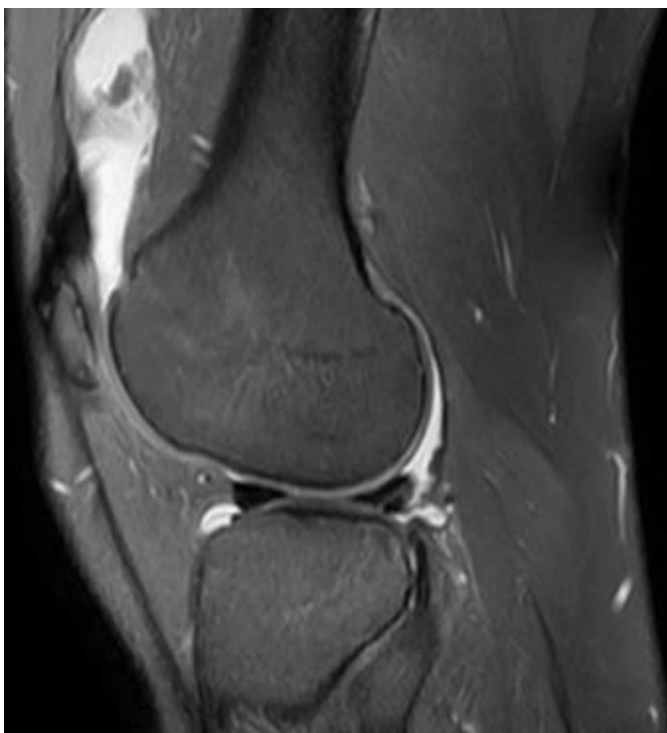

Figure 7: sagittal pd image showing double pcl sign in bucket handle tear in the posterior horn of mm.

