

Imaging findings of post covid-19 complications

¹Dr. Anand S H, Professor, Department of Radio-diagnosis, Sri Siddhartha Medical College, India

²Dr. Anugrah Suresh, Post-graduate, Department of Radio-diagnosis, Sri Siddhartha Medical College, India

³Dr. Banu Prakash, Professor, Department of Radio-diagnosis, Sri Siddhartha Medical College, India

⁴Dr. Ashwin Kumar, Assistant Professor, Department of Radio-diagnosis, Sri Siddhartha Medical College, India

⁵Dr. Anusha J, Assistant Professor, Department of Radio-diagnosis, Sri Siddhartha Medical College, India

⁶Dr. Anulatha Holla, Post-graduate, Department of Radio-diagnosis, Sri Siddhartha Medical College, India

⁷Dr. Roshika Maddeti, Post-graduate, Department of Radio-diagnosis, Sri Siddhartha Medical College, India

⁸Dr. Mayushree Dixit, Post-graduate, Department of Radio-diagnosis, Sri Siddhartha Medical College, India

Corresponding Author: Dr. Anugrah Suresh, Post-graduate, Department of Radio-diagnosis, Sri Siddhartha Medical College, India.

How to citation this article: Dr. Anand S H, Dr. Anugrah Suresh, Dr. Banuprakash, Dr. Ashwin Kumar, Dr. Anusha J, Dr. Anulatha Holla, Dr. Roshika Maddeti, Dr. Mayushree Dixit, “Imaging findings of post covid-19 complications”, IJMACR- July - 2023, Volume – 6, Issue - 4, P. No. 22 – 34.

Open Access Article: © 2023, Dr. Anugrah Suresh, et al. This is an open access journal and article distributed under the terms of the creative common’s attribution license (<http://creativecommons.org/licenses/by/4.0>). Which allows others to remix, tweak, and build upon the work non-commercially, as long as appropriate credit is given and the new creations are licensed under the identical terms.

Type of Publication: Original Research Article

Conflicts of Interest: Nil

Abstract

Background: The novel corona virus was deadly infection which caused widespread morbidity and mortality on its own. A great number of the survivors of the disease were also not spared by the post-covid complications that followed.

Aim: The purpose of this study is to describe & document the common imaging patterns in the complications of post covid-19 infection.

Method: We retrospectively evaluated the imaging and clinical data of 64 patients with post covid-19 complications referred to the department of Radio-diagnosis, Sri Siddhartha Medical College, Tumkur.

Results: The study helped in identification of the common complications in post covid-19 infections and also helped to describe the imaging findings in the complications identified. Mucor mycosis was diagnosed in 46 (71.8%) of the 64 patients followed by oligohydramnios in 7(10.9%) and pancreatitis in 6 (9.37%) respectively.

Conclusion: Imaging played a significant role in the detection, diagnosis, and assessment of virus-induced injury and associated complications. A thorough knowledge of diagnostic imaging hallmarks, atypical imaging features, multisystem manifestations and evolution of imaging findings helped clinicians to

understand the complications of newly emerged pandemic in a better way.

Keywords: Post covid-19, Post-covid Complications, SARS-cov-2, Corona virus, Pandemic

Introduction

In December 2019, In Wuhan City of China, cases of a novel coronavirus-associated pneumonia were first reported. On February 11, 2020, the World Health Organization (WHO) termed this new coronavirus disease as Coronavirus Disease 19 (COVID-19) and declared a pandemic on March 11, 2020.^{1, 2}

The virus quickly spread worldwide affecting the entire population. Two waves of Covid-19 were faced by the world in 2020 and 2021. Compulsory lockdowns and social distancing implemented by the respective governing bodies of each country was the corner stone in controlling the spread of the disease in the subsequent wave.

As of today, the number of cases has crossed 600 million worldwide with an estimated 6 million deaths as per the WHO. In India the number of cases has crossed 44 million and death toll of more than 500 thousand.²

Materials and methods

We retrospectively evaluated the imaging and clinical data of 64 patients with post covid-19 complications referred to the department of Radio-diagnosis, Sri Siddhartha Medical College, Tumkur. The imaging findings and clinical data are documented to describe the complications of covid 19, which includes Pneumothorax, Pancreatitis, Mucormycosis, cerebral infarcts, pneumo-mediastinum, IUD. Patients were selected for study if by means of Ultrasound, Computed Tomography (CT) scans and magnetic resonance (MR) images were available for review.

All these patients had MR imaging with a 1.5-T Siemens Essensa system. CT scan was done in GE revolution 16 machine & ultrasonography was done in GE Voluson S8 machine. In MRI scan, Multiplanar T1- and T2-weighted images.

All studies were reviewed by two radiologists, and the anatomic structures involved by the infection were defined by consensus. Clinical information about the presentation, management and evolution of disease was obtained from medical history in all case.

Inclusion criteria

1. All patients with a previously diagnosed seropositive and radiological positive Covid-19 disease in the last 6 months with new onset complaints.

Exclusion criteria

1. All patients of age less than 18 years
2. All patients with a previous history of Cerebrovascular accidents
3. All patients with history of chronic alcoholism and smoking
4. All obstetric patients with previously diagnosed complications and anomalies.

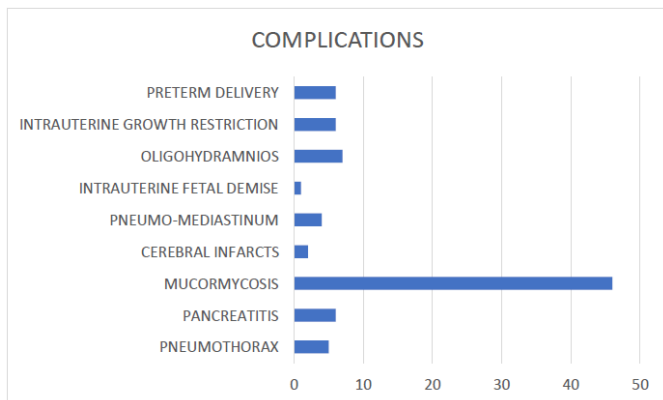
Results

The imaging findings and clinical data of this retrospective study of 64 patients described the following complications in Table I along with its graphical analysis (graph 1):

Table 1: Results of the study.

COMPLICATIONS	NO: OF CASES
PNEUMOTHORAX	5
PANCREATITIS	6
MUCORMYCOSIS	46
CEREBRAL INFARCTS	2
PNEUMO-MEDIASTINUM	4
INTRAUTERINE FETAL DEMISE	1
OLIGOHYDRAMNIOS	7
INTRAUTERINE GROWTH RESTRICTION	6
PRETERM DELIVERY	6

Graph 1: Graphical analysis of the complications.



The above mentioned are the most commonly identified among the spectrum of post-covid complications. The early detection helps to decrease the morbidity and mortality of the patient by directing prompt treatment and guiding the overall treatment of the patient. Hence the study brings to light the significance of imaging in patient’s developing post-covid complications.

Discussion

A. Pathophysiology

Sars-cov-2 is a highly pathogenic member of the coronavirus family. Due to the high mortality rate of the covid-19 pandemic, understanding the molecular pathogenesis of sars-cov-2 was of utmost importance for directing the treatment aspects as well as for the

formulation of preventive vaccines for the future. Coronaviruses is a member of a large family of single-stranded rna viruses which prevails in different animal species; infection primarily induces respiratory diseases within the host. The viruses are spherical or pleomorphic, with a diameter of 80–160

The distinctive feature of coronaviruses are the club-shaped spike projections emanating from the surface of the virion, which gives them the appearance of a ‘solar corona’. Coronaviruses are able to cross species barriers and has been proved to cause severe diseases in humans, principally mers and sars3

B. Viral life cycle

Sars-cov-2 virus gains entry into the host cells through interaction of its spike protein on its surface with the entry receptor ace-2 (angiotensin converting enzyme 2) in the presence of tmprss2 (transmembrane serine protease 2).

Proposed mechanisms for covid-19 caused by infection with sars-cov-2 include:

1. Direct virus-mediated cell damage. It has higher affinity for the respiratory tract, given the high presence of ace-2 receptors (its entry receptor) in most of the epithelial cell types of the airway, including the alveolar epithelial type ii cells located in the lung parenchyma.
2. Dysregulation of the raas (renin-angiotensin-aldosterone system) as a consequence of downregulation of ace-2 related to viral entry, which leads to decreased cleavage of angiotensin i and angiotensin ii
3. Endothelial cell damage and thromboinflammation
4. Dysregulation of the immune response and hyper-inflammation caused by inhibition of interferon signalling by the virus, t cell lymphodepletion, and the production of pro-inflammatory cytokines, particularly il-6 and tnfa.

C. Clinical presentation

The incubation period for covid-19 is observed to be less than 14 days following exposure, with most cases manifesting 4–5 days after exposure.

The typical and atypical clinical presentations of covid-19 cases in a hospital setting include mainly fever, fatigue, cough, anorexia, myalgia, dyspnea, anosmia and dysgeusia, diarrhea, abdominal pain, sore throat, headache and nausea and vomiting. However, it is crucial to keep in mind that a large percentage of patients may present with no symptoms at the time of detection of covid-19 will become symptomatic later.

The most common symptoms at presentation (in 85-90% of cases) are fever, cough, and shortness of breath. Patients with mild to moderate disease presents with constitutional symptoms and the possible development of mild pneumonia. Whereas symptoms of severe disease include severe dyspnea leading to hypoxia and imaging showed >50% lung involvement within 24–48 hours of symptom onset.⁴

D. Diagnosis of covid

The diagnosis tools available so far have been based on 1) viral gene detection, 2) human antibody detection, and 3) viral antigen detection, among which the viral gene detection by rt-pcr has been found as the most reliable technique.

However, in the second wave of the covid-19 pandemic, we observed that a significant proportion of patients who were symptomatic yet rt-pcr negative were still covid-19 positive as per imaging findings, hereby stressing the importance of imaging in covid-19 suspected cases.

The diagnosis of covid-19 in imaging was done by computed tomography and the guideline followed for the diagnosis and classification of covid-19 disease was named co-rads (table 2). Co-rads helps to assign scores

from 1 to 5 in suspected cases of covid-19 which classifies the patient as very low suspicion (score 1) to very severe disease (score 5) a final score of 6 was added and assigned to cases which are rt-pcr proven cases of covid-19.^{5,6}

Table 2: CO-RADS Scoring in Covid-19.

CO-RADS SCORE ⁵	CT FINDINGS	LEVEL OF SUSPICION
CO-RADS 1	Normal CT or findings of non-infectious disease	NO
CO-RADS 2	No Ground glass opacities. Findings consistent with other infections: bronchiectasis, tree-in-bud etc.	LOW
CO-RADS 3	Ground glass opacities present. Findings indicating infection like consolidations also, suggestive of widespread bronchopneumonia, lobar pneumonia etc.	INTERMEDIATE
CO-RADS 4	Unilateral ground glass opacities Multifocal consolidations without any other typical finding	HIGH
CO-RADS 5	Bilateral Ground glass opacities and consolidations.	VERY HIGH
CO-RADS 6	Bilateral Ground glass opacities	PCR +

E. Pancreatitis

Viral pancreatitis can be caused by from mumps, measles, coxsackie, epstein - barr virus, and hepatitis-a virus. Pancreatitis has been observed in patients with a history of covid 19 infection and a female preponderance is also noted (table 3).

Pathogenesis⁷:

1. Direct local viral replication
2. Indirect mechanism: systemic failure
3. More prone for injury due to excessive ace 2 inhibitor receptor.

Most common clinical presentation: fever, abdomen pain, vomiting.

Table 3: comparison of gender predilection in present and existing studies.

Gender predilection in other study ⁸	Gender predilection in present study
Female > Males	Females > Males 4 out of 6 female patients (80%)

Most common type of pancreatitis: Acute interstitial edematous pancreatitis (Fig. 1 to 5), CT severity scoring of mild disease (in 6/6 patients). Splenic vein thrombosis

was noted in one case (Fig. 6). The common imaging findings in acute pancreatitis is described in Table 4 .

Table 4: Imaging findings in Ultrasonography and CECT Abdomen are described below7,8:

Ultrasonography	CECT abdomen
Bulky edematous pancreas	Enlarged pancreas
Hypoechoic	Uniform post contrast enhancement
Increased vascularity	Peri pancreatic fat stranding

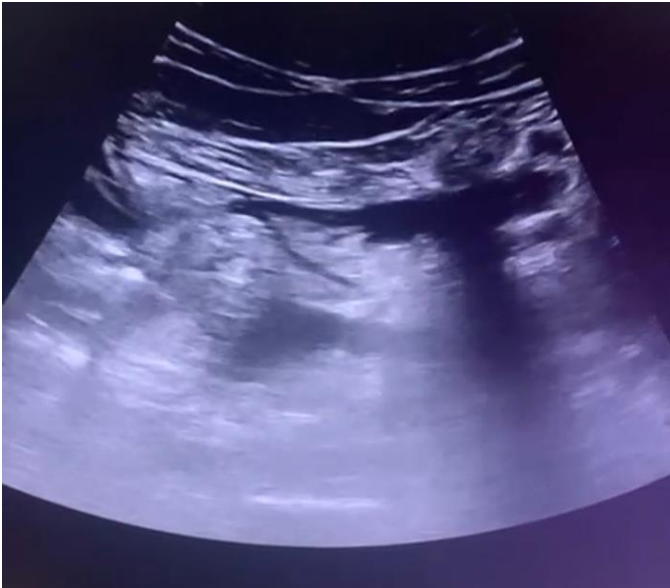

Fig. 1: Bulky and edematous pancreas.

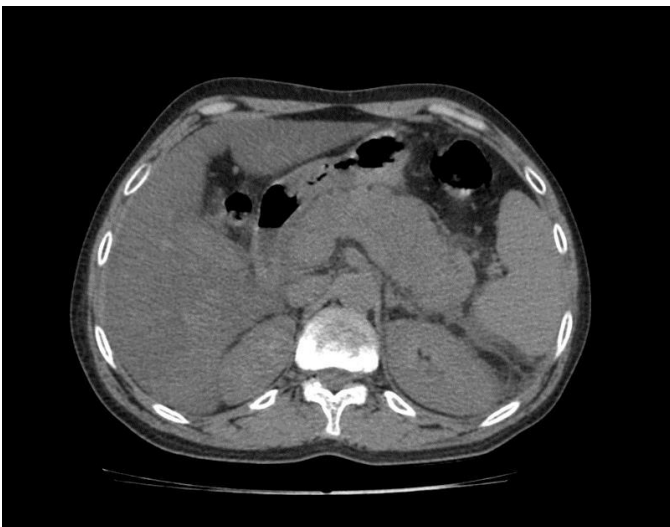


Fig. 2: CECT Abdomen Axial section plain reveals diffusely bulky pancreas with mild peripancreatic fat stranding and peri-pancreatic free fluid seeping into left anterior para renal space and peri splenic area.

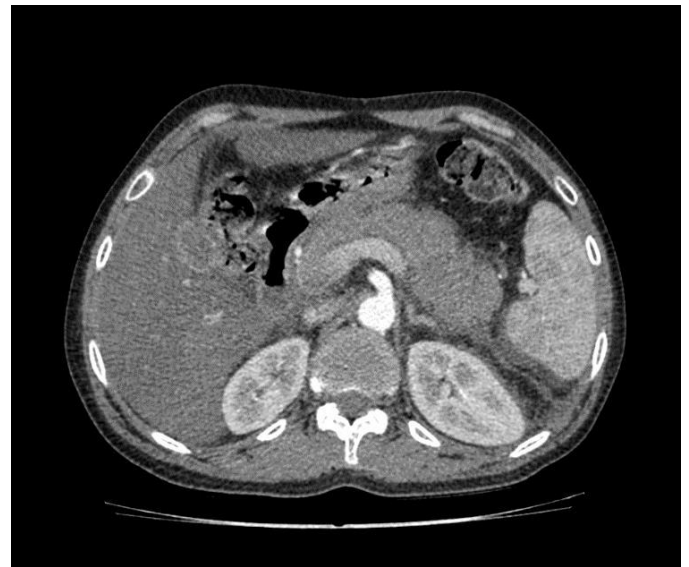

Fig. 3: CECT Abdomen Axial section arterial phase of the same patient reveals diffuse homogenous enhancement of the bulky pancreas with fat stranding and free fluid as described above.

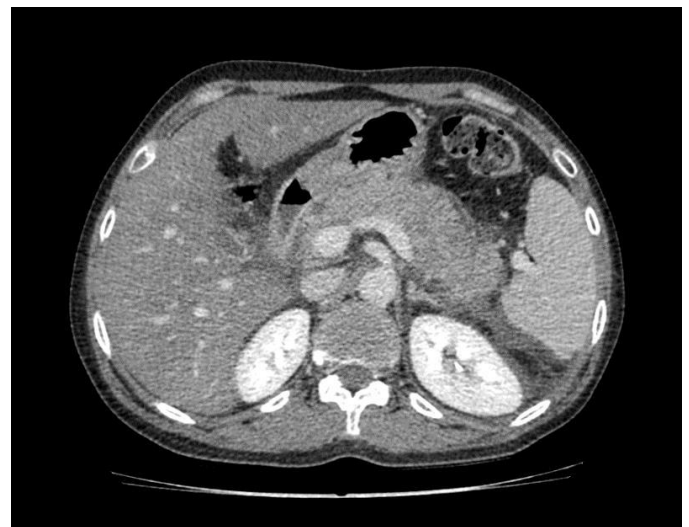

Fig. 4: CECT Abdomen Axial section venous phase of the same patient as above reveals bulky pancreas with homogenous enhancement with areas of pancreatic perfusion defects in the body and tail.

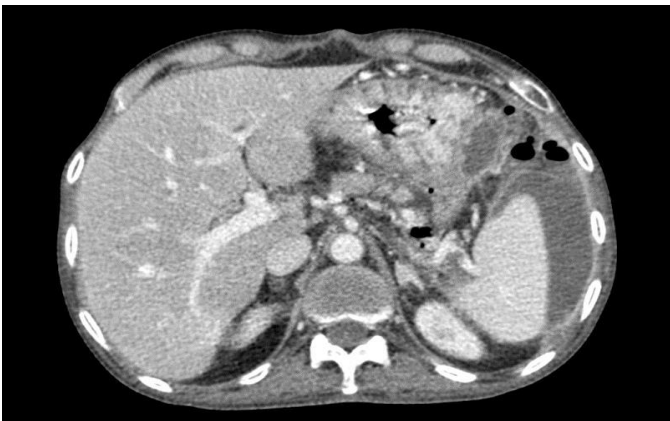


Fig. 5: CECT Abdomen Axial section venous phase in a male patient reveals a filling defect noted in the splenic vein with peri-splenic and omental collaterals causing hypodense lesion with contained air cavities seen in the superior part of spleen- Suggestive of splenic infarct.

F. Mucormycosis

Rhinocerebral mucormycosis is an acute, lethal opportunistic fungal infection mainly seen in diabetic or immunocompromised patients (due to defective phagocytosis), caused by *Absidia*, *Mucor*, and *Rhizopus*.⁹

Clinical symptoms include headache, low-grade fever, facial swelling and chemosis. The causes of rhino cerebral Mucor mycosis are increased in covid 19 patients due to use of corticosteroids.⁹

The common imaging findings in Mucormycosis are summarised below in Table 5. MRI is the primary modality of diagnosis of Mucormycosis (Fig. 6 to 11)

Infection enters through nasal cavity, spreads to adjacent para nasal sinuses, orbit (Table 6). It can cause necrotising fasciitis and angio invasion leading to rapid intracranial spread, orbital involvement, vascular phenomenon like cavernous sinus thrombosis⁹,

Stages of Mucormycosis as per Rupa et al [11]:

Stage 1: localized to the nasal cavity and paranasal sinuses.

Stage 2: spread to the peri-sinus areas, which are completely resectable.

Stage 3: spreads into the intracranial cavity, sinuses- partially resectable.

Table 5: Common imaging findings in Mucormycosis⁹.

MRI:
Early stage - enhancing and non-enhancing mucosa of the sinuses.
Later stage: vascular involvement-mucosal ischemia- non enhancing turbinates: Black turbinate sign iso- hyperintense signal intensities in T1W and T2W images (presence of manganese and iron in the fungal elements)
Extensive soft tissue edema with fat stranding of the face.
Orbital involvement: enhancing orbital contents, inflammatory collection fat stranding, optic neuritis.
CT: Skull base involvement -with bony destruction
Periantral soft tissue infiltration - invasive fungal sinusitis
Angio: Non enhancing sinuses and vessels due to presence of thrombus
Complications with intracranial extension: Brain abscess (hypodensity in CT), Infarct (MRI-FLAIR: hyperintense with diffusion restriction)

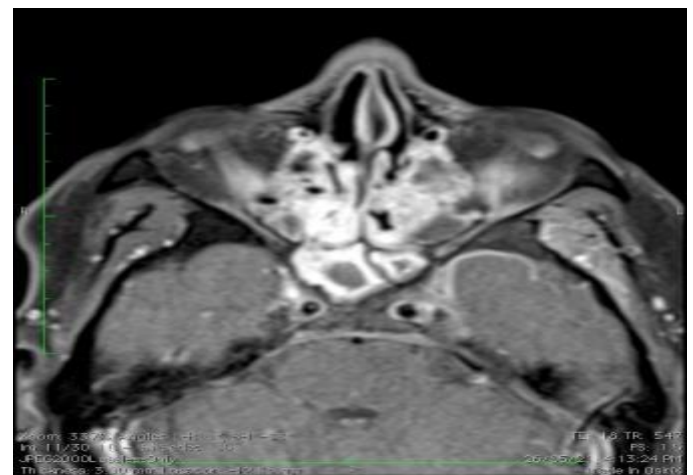

Fig. 6 (Axial section) reveals: Mucosal thickening and collection noted in the ethmoidal and sphenoid sinuses with non-enhancing collection within the sphenoid and left ethmoidal sinuses.

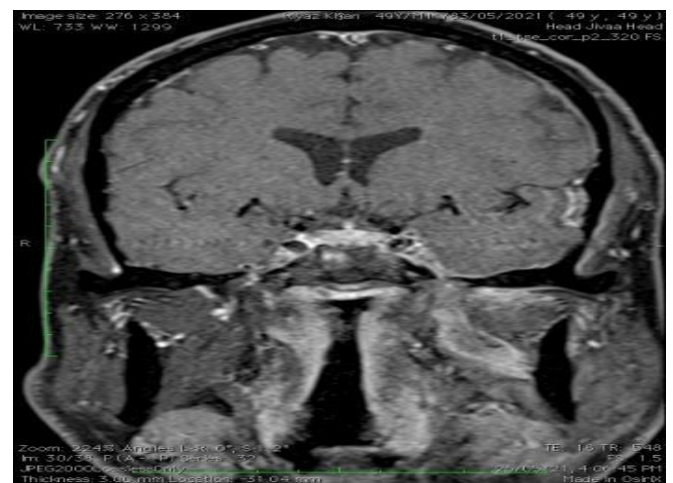

Fig. 7 (Coronal section) reveals: Enhancing soft tissue component noted in the left pterygo-maxillary region with involvement of left pterygoid muscles.

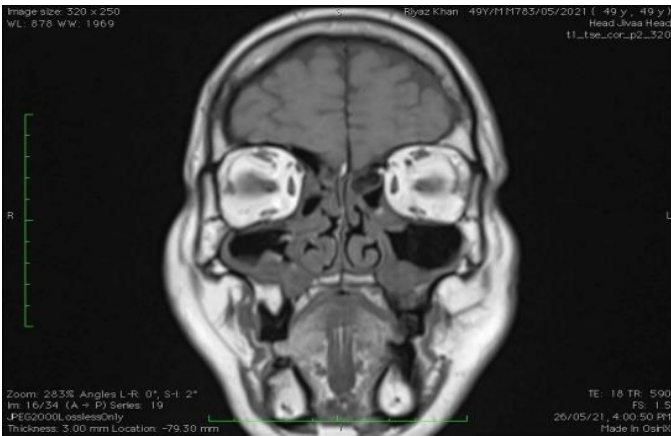


Fig. 8 (Coronal section) reveals: Mucosal thickening in bilateral maxillary and ethmoidal sinuses suggestive of sinusitis with few areas of T1 hyper intensities within the sinuses.

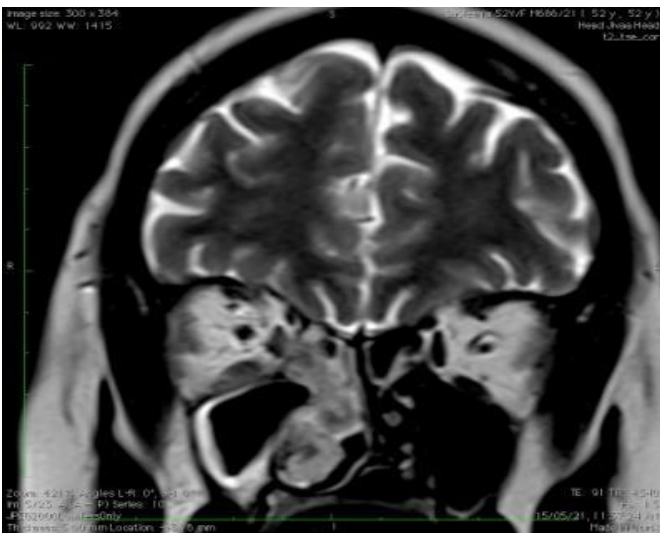


Fig. 9 (Coronal section) reveals: Mucosal thickening in right ethmoidal and maxillary sinuses s/o sinusitis with heterogenous single intensities, bony erosion of right laminae papyraceae extending in to right orbital cavity.

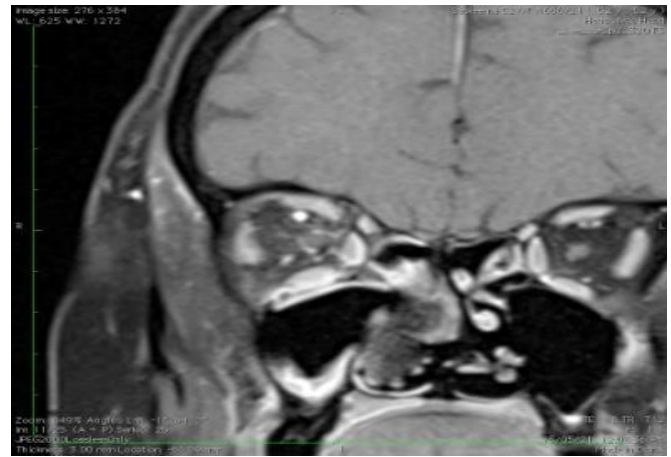

Fig. 10 (Coronal section) reveals: “Black turbinate sign”- hypo intensities of the right inferior turbinate with loss of normal architecture. Hypointense lesion/collection noted in the right lower ethmoidal sinus and nasal cavity along with mucosal thickening of the right maxillary sinus

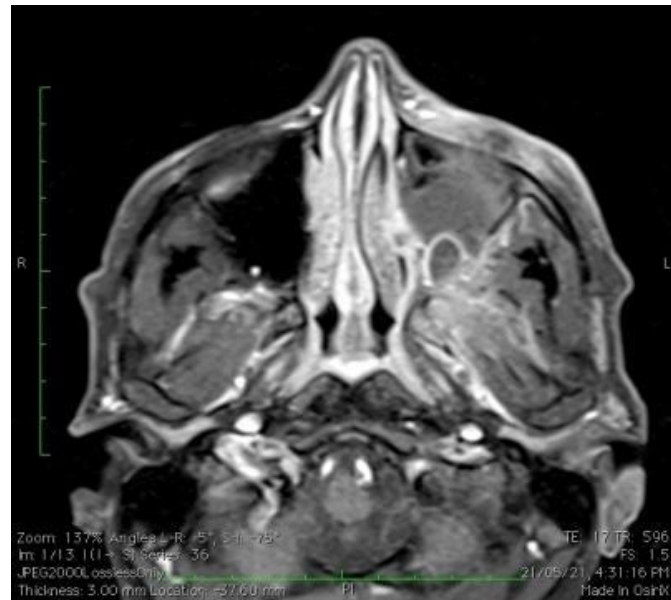

Fig. 11 (Axial section) reveals: Non enhancing collection in the left maxillary sinus causing bony destruction of the anterior and postero-lateral wall extending in to infra temporal fossa with involvement of the pterygo-maxillary fissure.

Table 6: Tabulation of the involvement of various structures in Mucormycosis in the present study.

Structure involved in our study	No of patients (46)
Maxillary sinus	38
ethmoid sinus	37
sphenoid sinus	30
frontal sinus	28
Bony erosions	30
Orbital involvement	18
Pterygo-maxillary fissure involvement	35
Black turbinate sign	28
Intracranial involvement	10
Intraparenchymal involvement	2

Accurate diagnosis using multimodality imaging like CT for bony involvement, MR with contrast to delineate extent of spread, vascular involvement, orbital involvement, intracranial extension will help to stage the disease which will give clear idea regarding need for surgical debridement and treatment approach¹⁰

G. Complications of covid 19 on pregnancy (maternal and fetal outcomes)

Mothers tested positive for COVID 19 virus during pregnancy showed multiple complications. Lama et al 1 mentioned complication such as maternal mortality, maternal intubation due to hypoxia, miscarriage, preterm delivery, small for gestational age (Table VII).

Elizabeth et al 12 concluded that COVID 19 in term patients admitted for safe confinement shows placental histopathological abnormalities namely vascular malperfusion, villitis. It is hypothesized that placental abnormalities are due to severe systemic inflammatory disorders resulting in hypercoagulable states and systemic microthrombi formation including placenta.¹² Pregnancy increases disease morbidity and symptoms due to physiological changes in pregnancy, and cardiopulmonary changes¹

Wang et al 1 described that there is no evidence of transplacental spread of infection to fetus during gestational period and delivery¹.

Multiple studies have shown that mode and timing of delivery should be decided based on patients' clinical status. However, most of babies delivered by LSCS due to maternal hypoxia, early cord clamping can reduce risk of fetal viral transmission¹

Our study showed intrauterine growth restriction, oligohydramnios, preterm birth and intrauterine fetal demise in COVID positive mother. There was no history of any fetal anomalies and other obstetric risk factors other than covid positive status. To avoid further complications during delivery, all patients underwent lower segment caesarean sections in dedicated OT for COVID positive cases during pandemic.

Table 5: Tabulation of the distribution of complications in the 8 antenatal cases observed in the present study and their mode of deliveries

Antenatal Complication	Number of cases	Mode of delivery
Intrauterine growth restriction	6	Lower Uterine Caesarean Section
Oligohydramnios	7	Lower Uterine Caesarean Section
Intrauterine fetal demise (Third Trimester)	1	Lower Uterine Caesarean Section
Preterm birth	6	Lower Uterine Caesarean Section

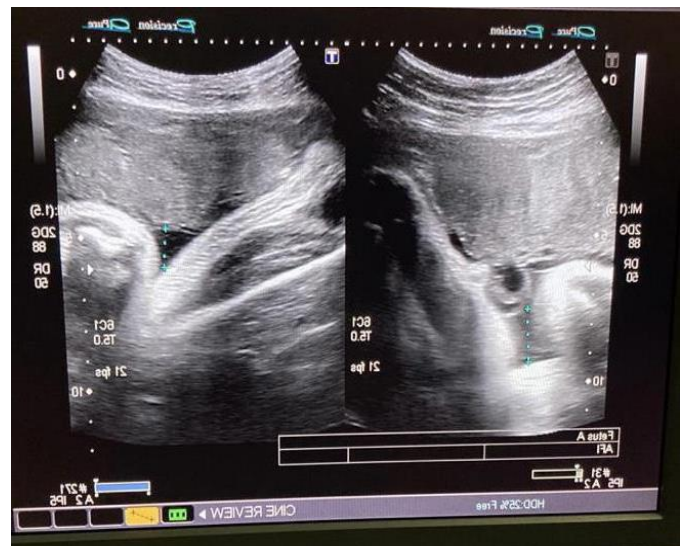

Fig. 12

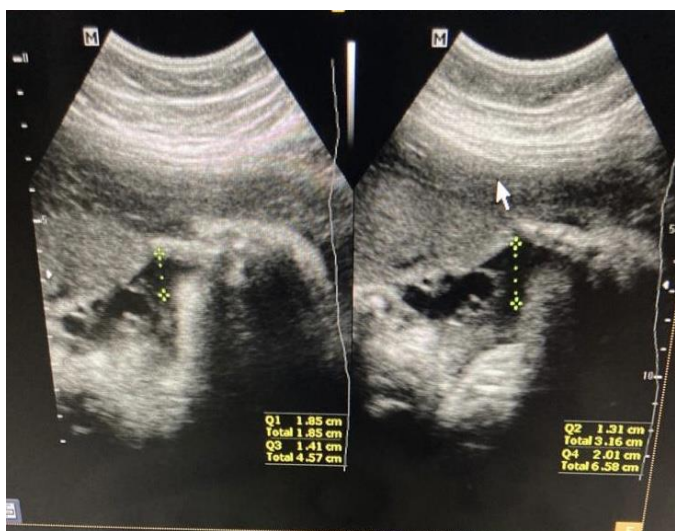


Fig. 12 & 13: Deepest vertical pocket less than 2cm which is indicative Oligohydramnios

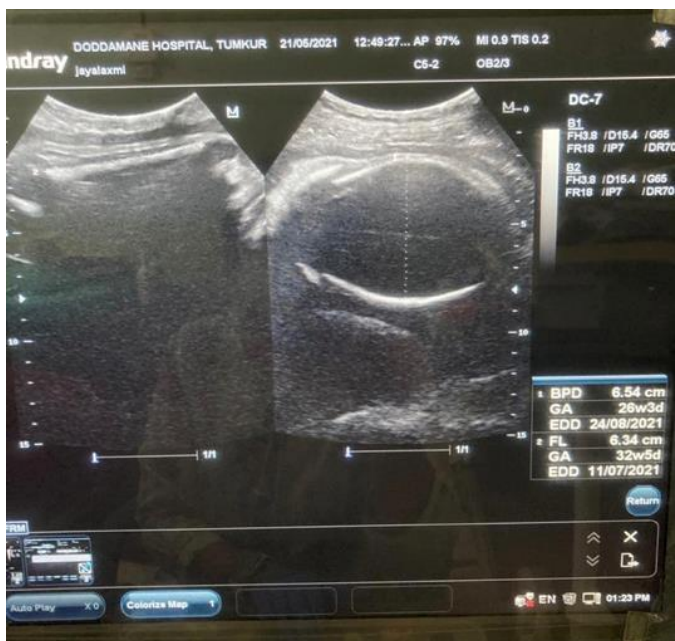

Fig. 14: Antenatal Ultrasonography reveals Fetal BPD corresponding to 26 weeks, fetal femur length corresponding to 32 weeks, suggestive of Asymmetric Intrauterine Growth Restriction

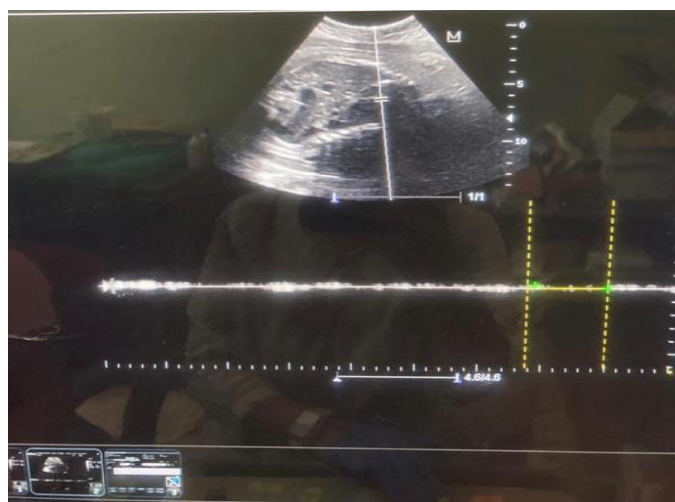


Fig. 15: Antenatal Ultrasonography reveals Absent fetal heart rate which is confirmatory of intrauterine fetal demise

H. Neurological manifestations

SARS-cov-2 induced coagulopathy has been a significant contributor to the development of neurologic manifestations in patents with a history of Covid 197. The most common neurologic complications in Post covid-19 patients are listed in Table VIII, of which Acute stroke (Fig. 16 to 20) was the most common. Table 9 summarises the various imaging findings of common neurologic complications.

Table 8: Most common neurological manifestations in covid-19

Neurological manifestations
<ul style="list-style-type: none"> Stroke (most common)-large area, lacunar infarcts, water shed infarcts (Large infarcts - 45%, lacunar infarcts 24% and haemorrhagic stroke 24%)⁷ PRES Viral encephalitis-temporal lobes, cerebellar peduncles most common Post infectious demyelination Post hypoxic leukoencephalopathy Metabolic and toxic encephalopathy Venous thrombosis

Table 9: Imaging findings:

Complication	COMPUTED TOMOGRAPHY	MRI
Arterial thrombosis and ischemic stroke:	Hyperdense MCA sign Hypoattenuating areas in lobes and water shed areas -stroke	Sequences: T2/FLAIR/DWI/ADC /T1 C+/ANGIO T2 hyperintensities, DWI hyperattenuation, ADC-Hypoattenuation-restricted diffusion
Hemorrhagic stroke and venous thrombosis	Hemorrhagic hyperdense areas in hemorrhagic stroke Hyperdense linear hyper attenuating thrombus within cortical veins, cerebral vessels CT ANGIO: Filling defects	Microhemorrhage/blooming in GRE MR Venofilling defects

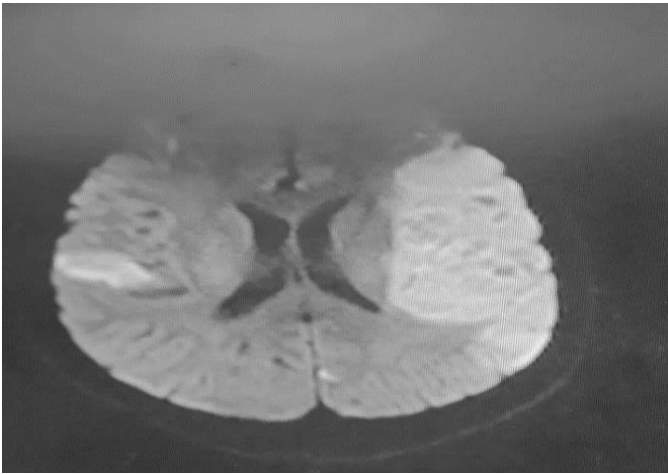


Fig. 16: A plain MRI axial Diffusion sequence reveals an area of hyperintensity in the left parietal region.

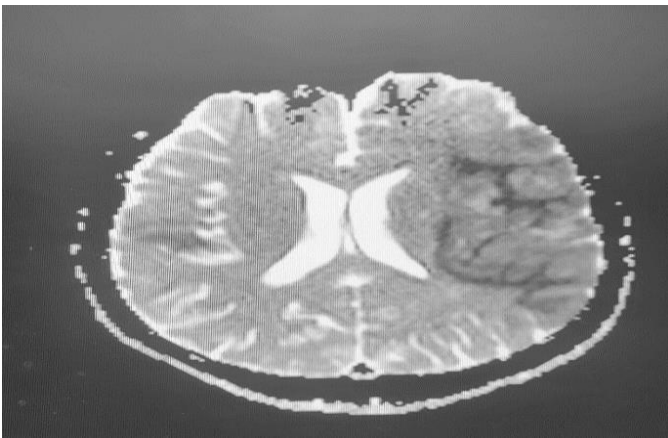


Fig. 17: A plain MRI axial ADC sequence of the same patient reveals corresponding area of hypointensity, indicative of an acute infarct

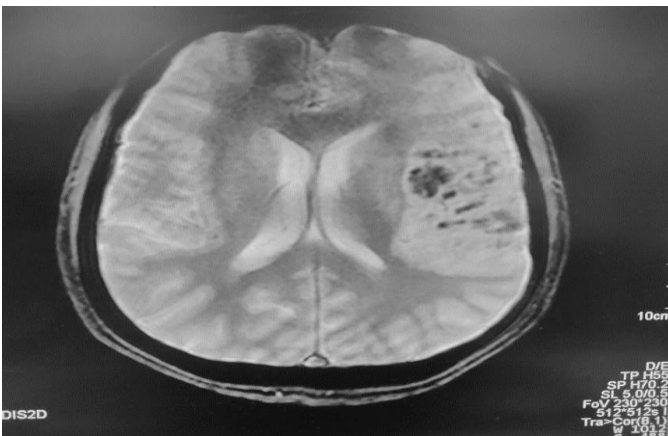


Fig. 18: A plain MRI axial SWI sequence of the same patient reveals blooming in the corresponding parietal lobe, indicative of hemorrhagic transformation.

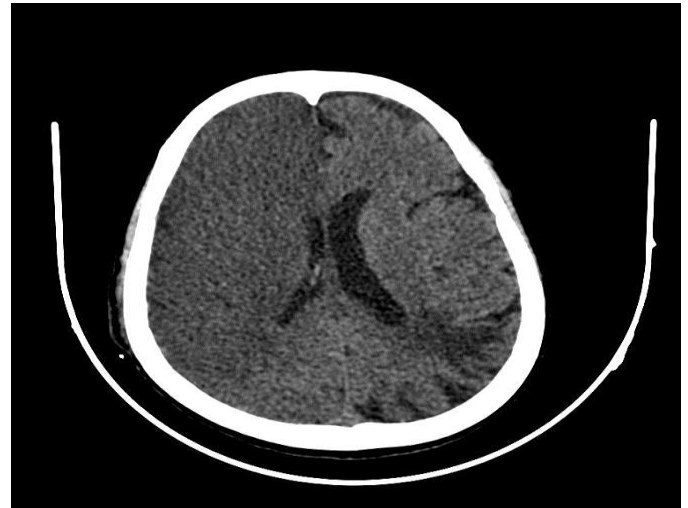

Fig. 19: CT Brain axial section plain study reveals loss of grey-white differentiation and sulcal effacement in the right frontal, right parietal, part of right temporal region involving right gangliocapsular region- Suggestive of large infarct.

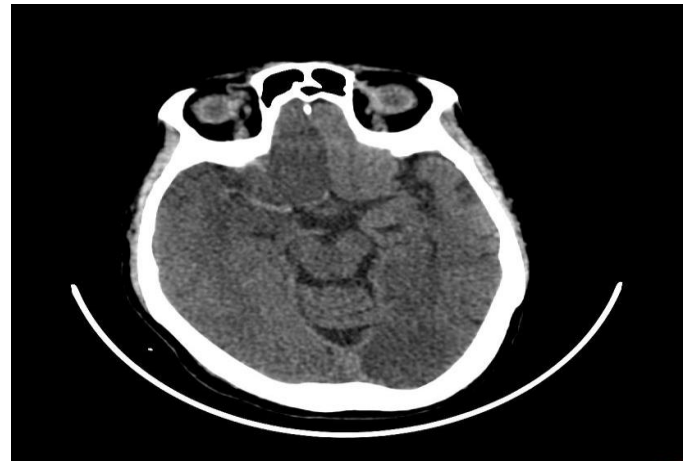

Fig. 20: CT Brain axial section plain study of the same patient reveals right MCA appeared mildly hyperdense- Hyperdense MCA Sign. A hypodense lesion with loss of grey-white differentiation and sulcal effacement is noted in the left occipital region- S/o acute infarct.

I. Thoracic complications

Lung is primary organ for development of COVID 19 Infection.

Diagnostic criteria for COVID 19 Infection are already discussed with CT Severity scoring which mainly

includes peripheral, lower lobe predominant ground glass opacities or consolidation. Secondary complications of COVID are mainly due to longer ICU admissions due to severe primary lung disease which can cause barotrauma leading to alveolar damage, pneumothorax (Fig. 22 and 23) and pneumomediastinum (Fig. 24). Patient can show features of pulmonary edema secondary to severe pneumonitis.^{4,7} Hypercoagulable states can result in pulmonary vessel thromboembolism⁴

Secondary fungal infections in already immunocompromised and ventilated patients are also seen⁴

Chest XRAY is primary screening modality in sick patients and ICU patients; however, CT Thorax is more sensitive to detect minute air collections, delineate consolidations, minute pleural effusions, pulmonary vascular embolism.

Chest Xray can show continuous diaphragmatic sign, large pneumothorax

CT chest imaging findings include air collections in lung pushing Lung and mediastinal structures to opposite side, air in mediastinum, air can be seen seeping to chest wall due to barotrauma. This will also demonstrate subcutaneous emphysema, pneumo-pericardium and potential tracheobronchial injuries, bilateral infiltrates typical of COVID-19.

Chronic sequelae and complication of COVID 19 infection includes fibrosis, reticular bands, volume loss of lungs

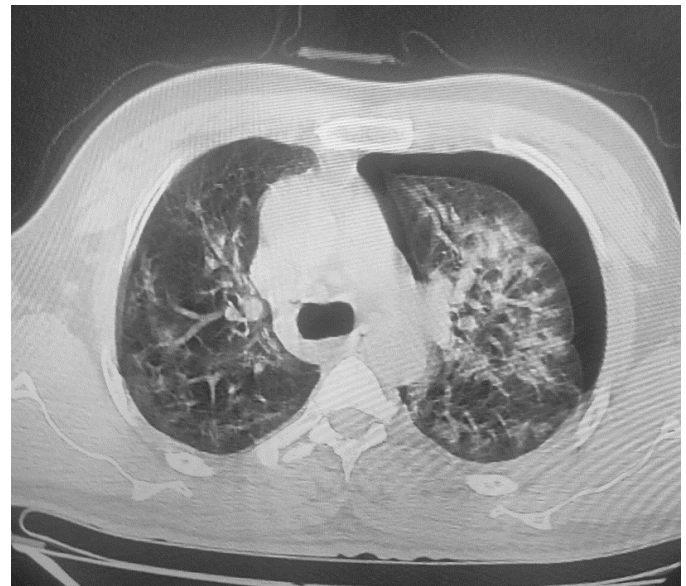

Fig. 21: Axial HRCT Thorax, plain reveals left pneumothorax with minimal mediastinal shift to the contralateral side. Bilateral lung parenchyma shows patchy ground glass opacity involving central and peripheral region suggestive of pneumonitis

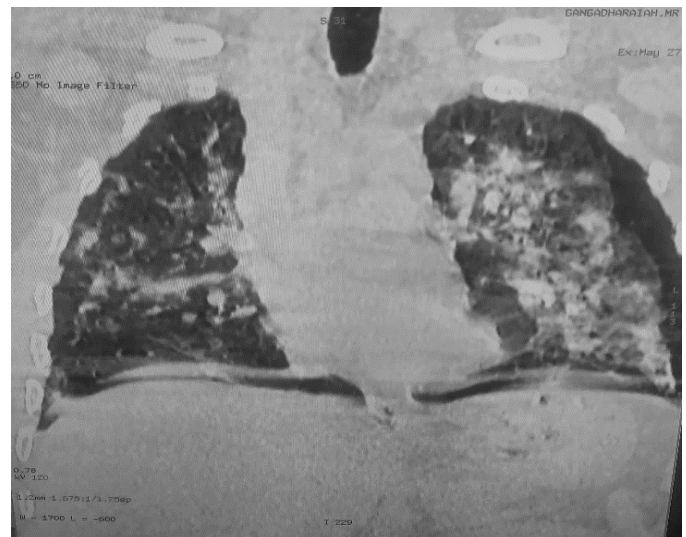


Fig. 22: Coronal HRCT plain thorax shows pneumothorax with volume loss in the left

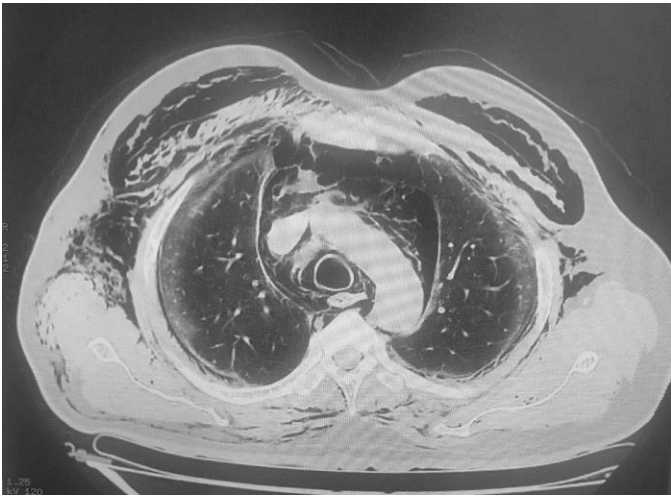


Fig. 23: Axial HRCT plain thorax reveals Pneumomediastinum with bilateral subpleural ground glass opacities and volume loss, surgical emphysema noted in bilateral chest wall expanding up to thoracic spine

Conclusion

Covid-19 disease is newly emerged pandemic with mutant strains arising every year. Even though it primarily manifested as pneumonitis during the outbreak in the initial days, it has shown to involve multiple organs. Few complications namely, rhinocerebral mucormycosis, pneumothorax, pneumomediastinum were seen emerging secondary to usage of steroids for treatment and barotrauma secondary to intubation in critically ill patients.

Few maternal pregnancy related complications were observed and studied in previously covid 19 positive mothers involving late trimesters. Knowledge regarding this helps in careful monitoring of the mothers and foetuses during pregnancy and take necessary precautions to avoid them. Understanding the multiorgan involvement pattern by a radiologist will give him a diagnostic tool when these complications present atypically, minimises under-diagnosis, avoids misinterpretation which not only guides the treating

physician/surgeon but also gives them an extra edge to look for other organ involvement. This will do a great deal in boosting patient care and hence drastically improving the surviving rates of the patients.

There is a need for further research regarding the pathophysiology of the disease which is still not fully understood in old and new strains

References

1. Wang CL, Wu CH, Wang CY, Wang CH, Long CY. Impact of COVID-19 on Pregnancy. *International journal of medical sciences*. 2021;18(3):763.
2. Lovato A, De Filippis C. Clinical presentation of COVID-19: a systematic review focusing on upper airway symptoms. *Ear, Nose & Throat Journal*. 2020 Nov;99(9):569-76.
3. Gupta A, Madhavan MV, Sehgal K, Nair N, Mahajan S, Sehrawat TS, Bikdeli B, Ahluwalia N, Ausiello JC, Wan EY, Freedberg DE. Extrapulmonary manifestations of COVID-19. *Nature medicine*. 2020 Jul;26(7):1017-32.
4. Revzin MV, Raza S, Warshawsky R, d'agostino C, Srivastava NC, Bader AS, Malhotra A, Patel RD, Chen K, Kyriakakos C, Pellerito JS. Multisystem imaging manifestations of COVID-19, part 1: viral pathogenesis and pulmonary and vascular system complications. *Radiographics*. 2020 Oct;40(6):1574-99.
5. Prokop M, Van Everdingen W, van Rees Vellinga T, Quarles van Ufford H, Stöger L, Beenen L, Geurts B, Gietema H, Krdzalic J, Schaefer-Prokop C, Van Ginneken B. CO-RADS: a categorical CT assessment scheme for patients suspected of having COVID-19—definition and evaluation. *Radiology*. 2020 Aug;296(2):E97-104.

6. Elnaggar ME, Rawy AM, El-Melouk MS, Al-Tabbakh AS, Abdel-Khalik HA, Abdelkhalek EF, Elsayw RE. CO-RADS score and its correlation with clinical and laboratory parameters in patients with COVID-19. *The Egyptian Journal of Bronchology*. 2023 Dec;17(1):1-9.
7. Revzin MV, Raza S, Srivastava NC, Warshawsky R, d'agostino C, Malhotra A, Bader AS, Patel RD, Chen K, Kyriakakos C, Pellerito JS. Multisystem imaging manifestations of COVID-19, part 2: from cardiac complications to pediatric manifestations. *Radiographics*. 2020 Nov;40(7):1866-92.
8. Georgakopoulou VE, Gkoufa A, Garmpis N, Makrodimitri S, Papageorgiou CV, Barlampa D, Garmpi A, Chiapoutakis S, Sklapani P, Trakas N, Damaskos C. COVID-19 and acute pancreatitis: A systematic review of case reports and case series. *Annals of Saudi Medicine*. 2022 Jul;42(4):276-87.
9. Saneesh PS, Morampudi SC, Yelamanchi R. Radiological review of rhinocerebral mucormycosis cases during the COVID-19 Pandemic: A single-center experience. *World Journal of Radiology*. 2022 Jul 7;14(7):209.
10. Alekseyev K, Didenko L, Chaudhry B. Rhinocerebral mucormycosis and COVID-19 pneumonia. *Journal of medical cases*. 2021 Mar;12(3):85.
11. Singh AK, Singh R, Joshi SR, Misra A. Mucormycosis in COVID-19: a systematic review of cases reported worldwide and in India. *Diabetes & Metabolic Syndrome: Clinical Research & Reviews*. 2021 Jul 1;15(4):102146.
12. Patberg ET, Adams T, Rekawek P, Vahanian SA, Akerman M, Hernandez A, Rapkiewicz AV, Ragolia L, Sicuranza G, Chavez MR, Vintzileos AM. Coronavirus disease 2019 infection and placental histopathology in women delivering at term. *American journal of obstetrics and gynecology*. 2021 Apr 1;224(4):382-e1.