

Clinicopathological correlation of vocal cord lesions inpatients presenting with hoarsness of voice in a tertiary care centre – An Analysis of 100 Cases¹Dr Vidya S, ²Dr Anamta Sayeed, ³Dr Suchitra N Sheelan, ⁴Dr Sathish Kumar S**Corresponding Author:** Dr Vidya S**How to citation this article:** Dr Vidya S, Dr Anamta Sayeed, Dr Suchitra N Sheelan, Dr Sathish Kumar S, “Clinicopathological correlation of vocal cord lesions inpatients presenting with hoarsness of voice in a tertiary care centre – An Analysis of 100 Cases”, IJMACR- May - 2024, Volume – 7, Issue - 3, P. No. 09 – 18.**Open Access Article:** © 2024, Dr Vidya S, et al. This is an open access journal and article distributed under the terms of the creative common’s attribution license (<http://creativecommons.org/licenses/by/4.0>). Which allows others to remix, tweak, and build upon the work non-commercially, as long as appropriate credit is given and the new creations are licensed under the identical terms.**Type of Publication:** Original Research Article**Conflicts of Interest:** Nil**Abstract**

Hoarseness of voice is one of the commonest symptoms encountered in the routine ENT practice. Numerous conditions can cause hoarseness, ranging from simple inflammatory pathologies to more serious systemic, neurologic, or malignant conditions involving the larynx. Evaluation of such patients requires a careful history, physical examination, and in many cases, videolaryngoscopy for further management. In our study we retrospectively analysed a series of 100 patients with vocal cord lesions, who had presented to our OPD with hoarseness of voice. About 58 out of 100 patients were diagnosed with benign pathologies and 42 with malignant conditions. The further management was done based on histopathological diagnosis. In this study apart from some common histopathological lesions, we also found some rare ones and treated accordingly. This study throws light on to the various possible laryngeal histopathological causes for hoarseness encountered in our institute.

Keywords: Histopathological, Hoarseness, Dysphagia**Introduction**

Hoarseness is defined as an altered vocal quality, pitch, loudness, or vocal effort which impairs communication or reduces voice-related quality of life. Any patient with hoarseness of two weeks duration or longer must undergo visualization of the entire larynx, specifically the vocal folds as most of the causes are in relation to the mass, margin and movement of the vocal folds.¹ Hoarseness is a symptom of utmost significance and calls for a separate consideration as a subject because of the frequency of its occurrence as a distant signal of malignancy and other conditions.² Benign conditions of the larynx constitute an intriguing array of lesions and have been defined as an abnormal mass of tissue in the larynx, the growth of which exceeds and is unmatched with that of normal tissue and persists in the same uncontrolled manner after cessation of stimuli which evoked the change.¹ The importance of benign lesions of the larynx lies in the importance of its function in

speaking and the contribution of the voice to one's identity. Hoarseness is often the first manifestation of conditions like the squamous cell carcinoma of the glottis, but it can be associated with cough, haemoptysis, laryngeal pain, or dysphagia.³ Various diagnostic tools including the fibre optic laryngoscopy can be a valuable tool in the diagnosis of functional voice disorders primarily affecting young adults, frequently non-vocal, non-professional resulting from vocal abuse. Surgical removal with microsurgical instruments remains the main line of treatment for laryngeal polyps, cysts and recalcitrant nodules.⁴ In our study, we have retrospectively analysed the data of patients presenting with laryngeal causes of hoarseness and their histopathologies obtained on biopsy.

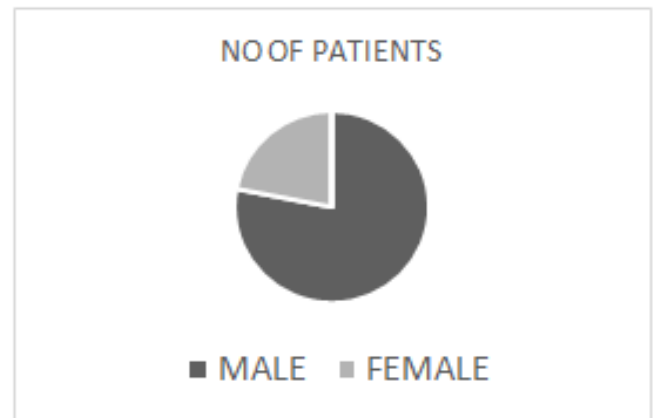
Materials and methods

A retrospective study was conducted in our tertiary care centre, in which data of hundred patients within a period of two years were analysed for the study. Inclusion criteria were patients with complaints of hoarseness who were diagnosed with true vocal cord lesion son Videolaryngoscope and had undergone direct laryngoscopy (DL) and biopsy or microlaryngeal surgery and biopsy in our institute. We analysed their clinical data such as demography, habits, clinical diagnosis based on videolaryngoscopy, the histopathology obtained on biopsy and their subsequent treatment.

Observations and Results

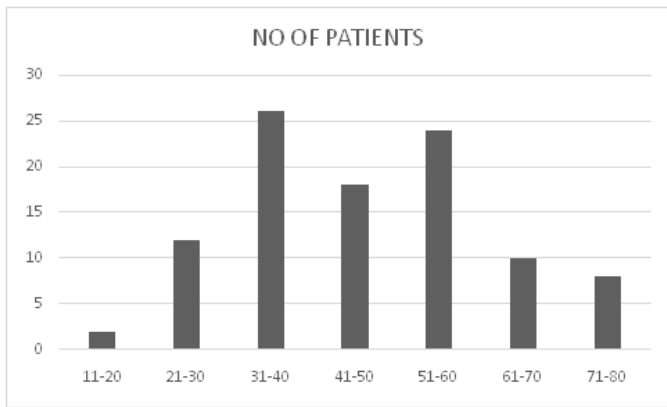
A total of hundred patients were included in the study out of which 78 were male and 22 were female patients.

Sex distribution	No of patients
Male	78
Female	22



Majority of the patients included in the study belonged to the age group of 31-40 years and 51-60 years of age. Most of the patients gave history of chronic vocal abuse and about 50 percent of the patients had a habit of smoking more the 2 packs per day and 1 patient had a prior history of intubation prior to developing the change in voice. The professions ranged from Shopkeepers to Homemakers and mostly involved vocal use and abuse of varying degree.

Age group (years)	No of patients
11-20	2
21-30	12
31-40	26
41-50	18
51-60	24
61-70	10
71-80	8



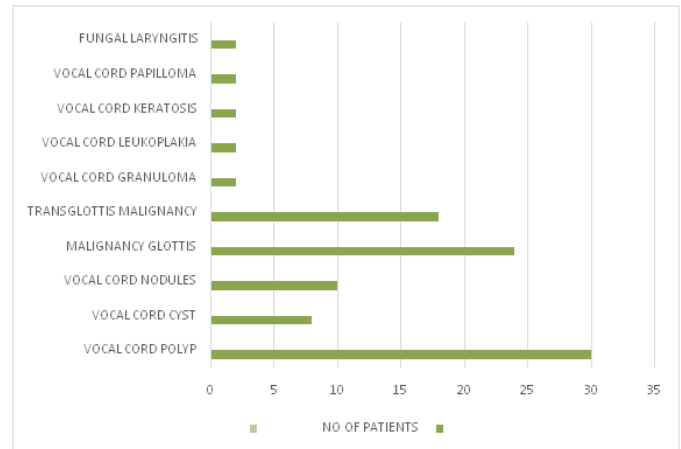
On Video Laryngoscopy, the following findings were noted

Clinical diagnosis	No of patients
Vocal cord polyp	30
Vocal cord cyst	8
Vocal cord nodules	10
Vocal cord growth under evaluation	46
Vocal cord white patch under evaluation	6

All the patients were posted for Microlaryngeal Surgery/Direct laryngoscopy and biopsy under general anaesthesia and the lesions were sent for Histopathological diagnosis. The diagnosis was as follows and the most common diagnosis being the Vocal Cord Polyp. Most of the patients had a unilateral lesion i.e. polyp except one having bilateral vocal cord polyp

Histopathological diagnosis	No of patients
Vocal cord polyp	30
Vocal cord cyst	8
Vocal cord nodules	10
Malignancy glottis	24
Transglottis malignancy	18
Vocal cord granuloma	2

Vocal cord leukoplakia	2
Vocal cord keratosis	2
Vocal cord papilloma	2
Fungal laryngitis	2



Benign/malignant	No of patients
Benign	58
Malignant	42

Patients having benign pathologies were all discharged after the histopathological diagnosis and were kept on regular follow up. Patient with fungal laryngitis were put on 2 weeks of oral itraconazole and were kept on regular follow up. The patients diagnosed with a malignant pathology were effectively managed according to the staging with necessary definitive surgery or radiation therapy in our hospital.

Pre Operative Pictures

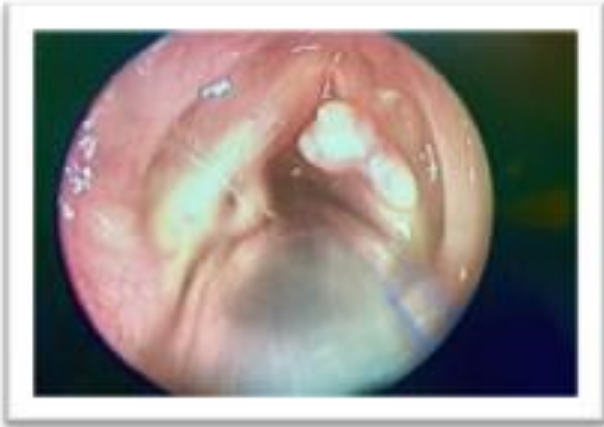

Figure 1: Vocal cord papilloma

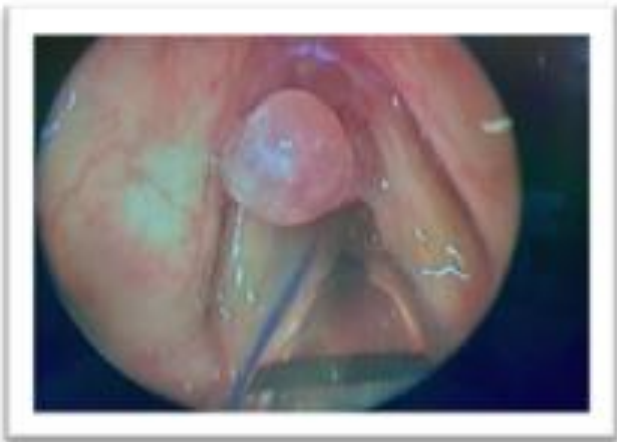

Figure 2: Vocal cord polyp

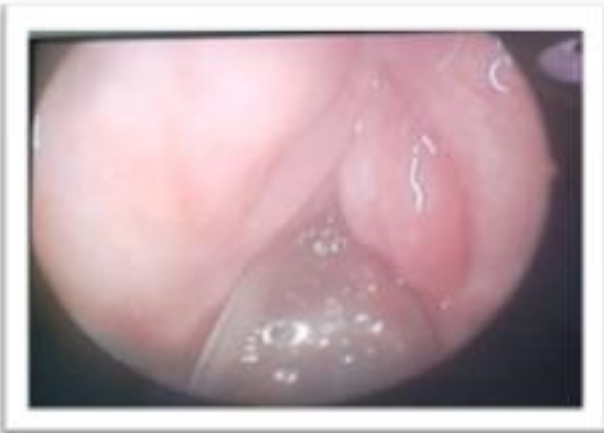

Figure 3: Vocal cord cyst

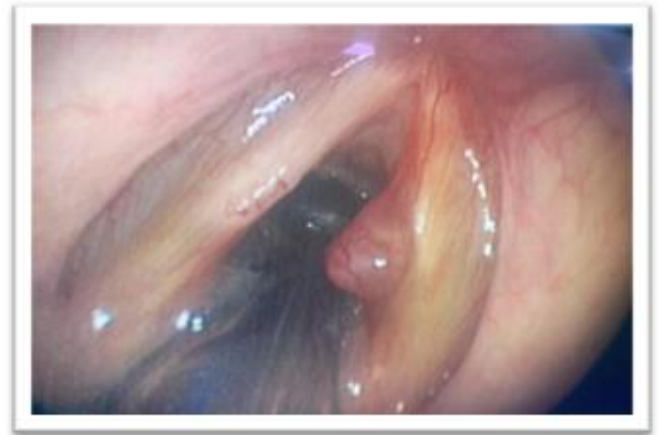

Figure 4: Reinke's Oedema

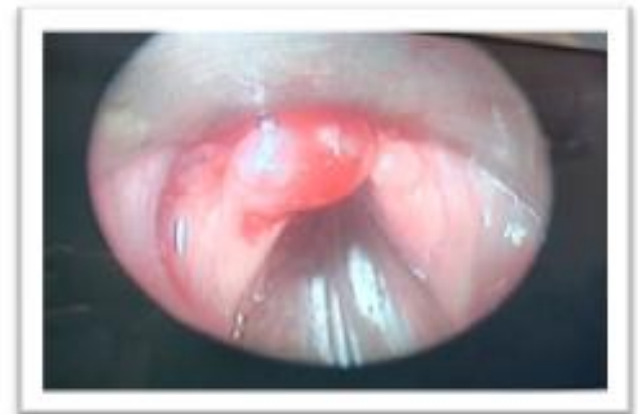

Figure 5: Bilateral Vocal cord polyp

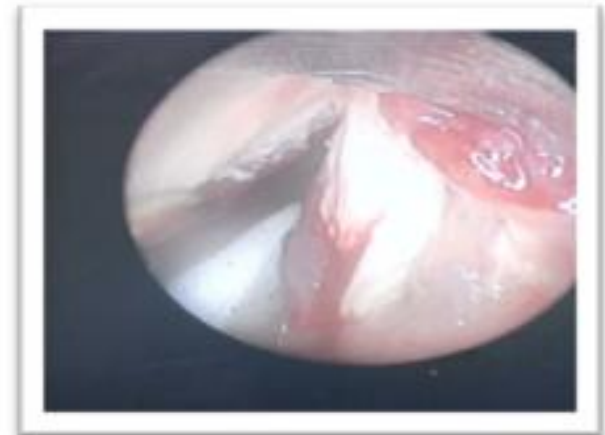

Figure 6: Fungal Laryngitis

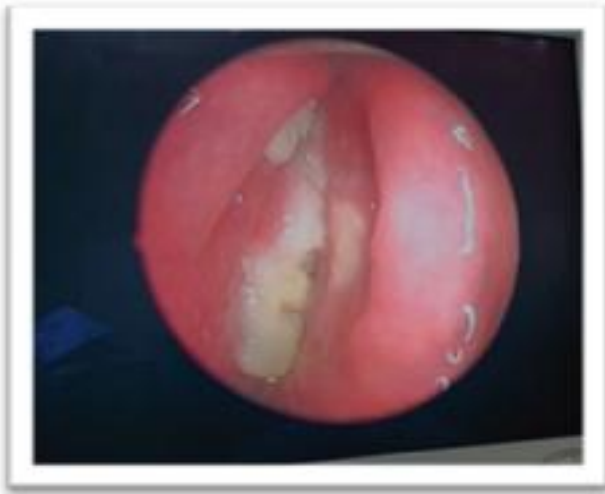

Figure 7: Malignancy Glottis

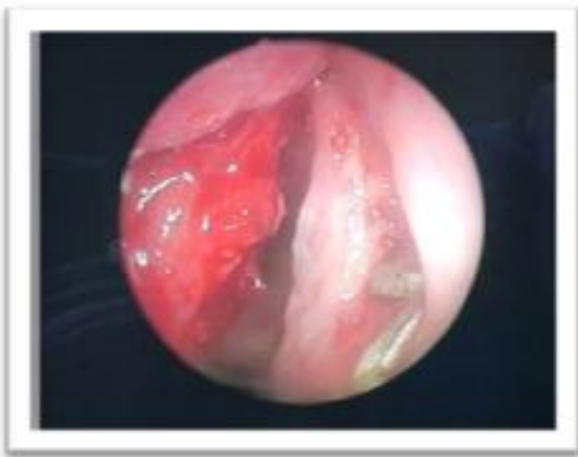


Figure 8: Malignancy glottis

Histopathological Photos

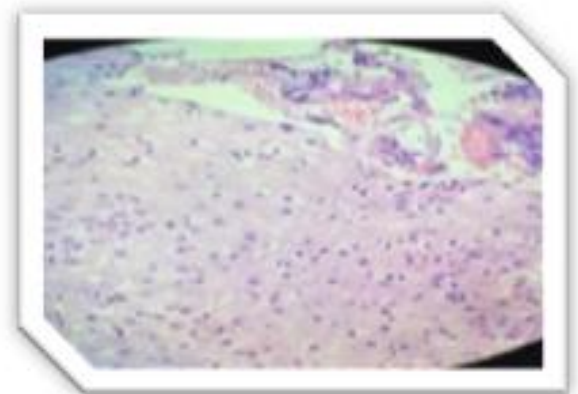


Figure 9: Dysplastic Squamous Epithelium With Infiltrating Tumour Cells In Small Nests And Cords

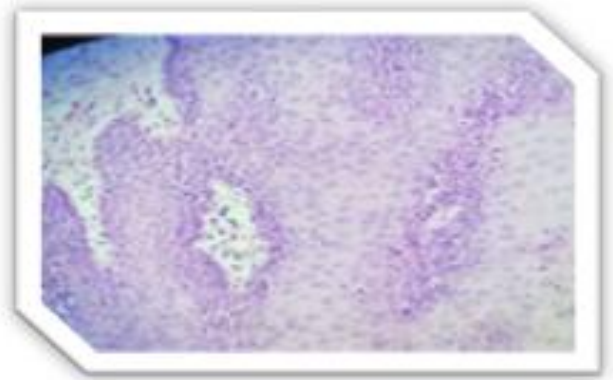


Figure 10: Full Thickness Dysplasia With Subepithelium Showing Dense Infiltration Of Neutrophils And Areas Of Necrosis 2

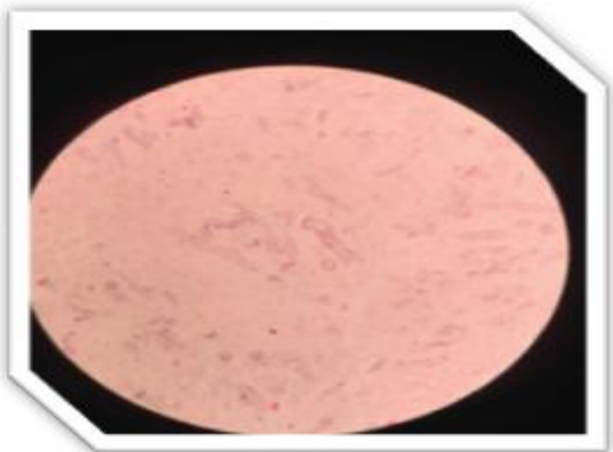


Figure 11: Fungal Elements With Broad Aseptate Hyphae

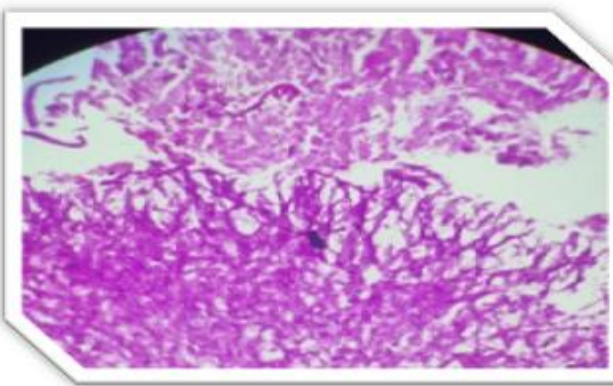


Figure 12: Fungal Elements With Broad Aseptate Hyphae



Figure 13: Hyperplastic Squamous Mucosa With Mild Reactive Cytological Atypia- s/o Vocal Cord Polyp

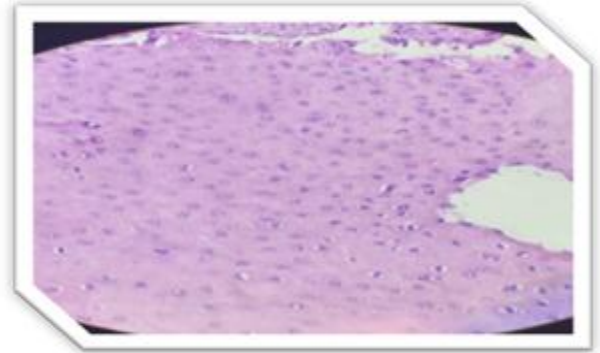


Figure 15: Nests of Dysplastic Cells- s/o Malignancy Glottis

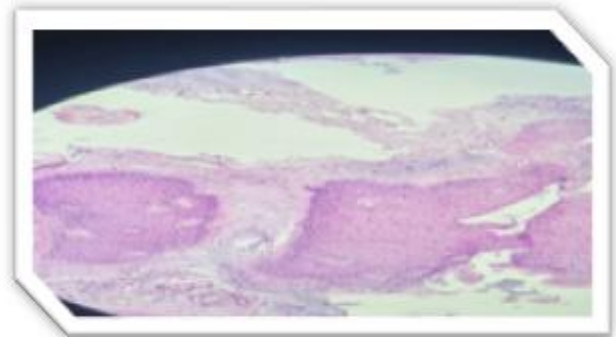


Figure 16: Moderate Dysplasia

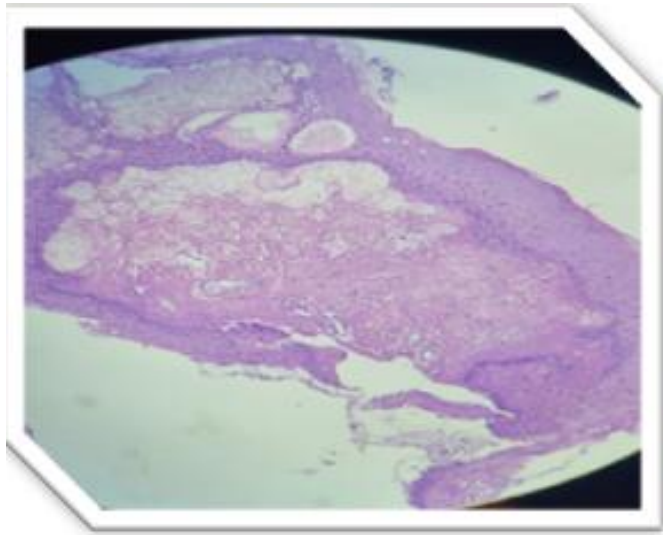


Figure 14: Hyperplastic Squamous Mucosa-s/o Vocal cord cyst

Discussion

Hoarseness is the term used to describe any alteration in the normal voice quality. It is comprehensive term which may imply breathiness, roughness, voice breaks or any other changes in the voice produced. The Term dysphonia is used by laryngologists to describe abnormal voice quality.¹ Any patient presenting with hoarseness of voice which is lasting longer than 2 weeks of duration, must be evaluated thoroughly.² Hoarseness of voice may be caused by a number of conditions which can be structural, functional, neurogenic, infectious, environmental, or neoplastic. Common causes of hoarseness, such as due to voice abuse or inflammation of larynx, can be benign and self-limiting, but more severe conditions such as laryngeal cancer, can be life-threatening. These all elements make the evaluation and

management of a hoarse patient both essential and cumbersome.⁴ The onset of hoarseness of voice can be broadly divided into acute and chronic. Many acute causes of hoarseness, such as viral and bacterial laryngitis, are self-limiting or medically treatable. Other conditions like ingestion of a foreign body or post-surgical trauma or epiglottitis may be accompanied by characteristic symptoms, such as the high fevers, sore throat, and drooling of saliva. Causes for hoarseness commonly include chronic voice abuse, smoke exposure, gastroesophageal or laryngopharyngeal reflux and neoplasm.³ Higher incidence (54%) of benign tumors was observed in occupations having chronic vocal abuse like teachers (16%), salesmen (16%), politicians (4%) and bus conductors (6%); in case of non-professional voice users, the highest incidence was observed in homemakers (24%).³ Cancer of the larynx comprises 2 to 5% of all malignant conditions diagnosed annually worldwide. Higher incidence is noted in countries like Spain, Italy, France, Brazil, India and the Afro-caribbean populations in parts of the USA (greater than 10 per 10,000). Low incidence locations (less than 2 per 100,000) include Japan, Norway and Sweden. All over the world, the peak incidence of malignancy larynx is highest in men aged between 55 to 65 years. The male-to-female ratio varies from 5 to 20:1, however in the last decades there has been a decrease in this ratio, because of an increase of incidence in women. There is a significant social economic difference, in that laryngeal cancer is twice as common in men with low socioeconomic status.⁵ Predisposing factors include vocal abuse, tobacco chewing, smoking, repeated infections of upper and lower respiratory tract, alcohol consumption etc.⁶ Acute laryngitis is a common self-limiting condition that commonly presents with

hoarseness of voice. Short-term vocal abuse and viral infections of the upper respiratory tract are the most common causes. Less common infectious causes are fungal and bacterial infections.⁷ Chronic laryngitis, which is often associated with a number of vocal cord lesions. Smoking, chronic voice abuse, tobacco chewing are the most common causes of chronic laryngitis. Less common causes can be other irritants, such as laryngopharyngeal reflux, allergies, and topically used inhaled corticosteroids.^{6,7} Vocal cord paralysis entails vocal fold immobility due to neurologic causes. It may occur because of injury to recurrent laryngeal nerve, superior laryngeal nerve or both. The injury to the nerve may be unilateral or bilateral. It may present as dysphonia, hoarseness, breathiness, throat pain, choking episodes, or vocal fatigue. Laryngeal findings may be tenuous and include asymmetric vocal fold movement, bowing, and rotation of the larynx.⁸ Laryngopharyngeal reflux (LPR) disease, is also known to cause otolaryngologic symptoms including voice change, sore throat, foreign body sensation, and dry cough. The increased frequency of this disease can be linked to the sedentary habits, intake of junk food, stress etc. Lifestyle modifications along with Proton pump inhibitors are commonly used for the management.⁹ According to Schindler A et al., benign vocal cord lesions are common and have important public health implications and impact patients day to day lives.¹⁰ They are more commonly seen in the age group of 21 to 40 years. Vocal cord nodule, polyp and cyst are more common in younger age group due to vocal abuse or overuse in them. Patients of older age group see Keratosis, granuloma and Reinke's edema due to their habits of smoking.¹¹ Vocal cord polyps are unilateral tissue proliferations which are present on the free margin of the

vocal fold. They occur because of microvascular trauma with local edematous remodeling processes and accompanying inflammation as a result of misuse of the voice. Vocal cord retention cysts occur when the excretory ducts of the mucous glands are blocked. The treatment of choice for polyps is microsurgical excision at the base. Cysts must be removed in its entirety with the capsule.¹²Reinkes edema is caused predominantly by tobacco smoking and mostly affects the women (80%) between the ages of 40 and 60 years. Microsurgical removal of the edema results in improvement of the pitch, resonance, and also resilience of the voice.¹²Laryngeal papillomatosis is a benign condition that can occur in both adults as well as children. It is commonly associated with infection with human papilloma virus. The primary benign, cauliflower like lesion occur commonly in the area of the vocal cords or extra laryngeally in the trachea, bronchi, or lungs. Microlaryngeal surgery and excision is the treatment. Laryngeal leukoplakia is presence of whitish patches which may be benign, precancerous, or malignant.^{7,12}Fungal laryngitis (FL) is a common clinical condition found amongst immunocompromised patients. The Primary fungal infection of the larynx is less commonly seen. It is commonly seen secondary to pulmonary or oropharyngeal infections. It may occur due to Candidiasis, Aspergillosis, Cryptococcal, Blastomycosis and Histoplasmosis. The predisposing factors include conditions altering the host immunity and other factors altering the mucosal barrier like Diabetes mellitus, Immunosuppressive medication like chemotherapy or systemic corticosteroids, nutritional deficiencies, AIDS, and Chronic lymphocytic leukaemia. Other susceptible conditions include previous radiotherapy, inhaled corticosteroids, gastro-oesophageal reflux, smoking and

trauma e.g. intubation . Prolonged use of antibiotics and laser treatment over the vocal cords can also predispose to fungal laryngitis. Treatment includes adequate dosage of antifungal medications, Vocal hygiene and voice therapy.¹³In our study, patients with fungal laryngitis had no significant history and rest of the physical examination was normal. Laryngeal cancer comprises 30%-40% of all the head and neck malignancies. It is the most commonly occurring malignancy in otolaryngology. The main predisposing factors for laryngeal malignancy are tobacco use, excessive alcohol consumption, gastroesophageal reflux, Plummer-Vinson syndrome, exposure to heat, chemicals, and some viral infections.¹⁴In the management of early stages of laryngeal cancers, radiotherapy, open partial laryngectomy and transoral laser surgery are the three main treatment modalities. In advanced stage laryngeal cancers, there is a recent drift from total laryngectomy plus postoperative radiotherapy, to organ preserving chemoradiotherapy mainly for T3 tumors. For tumors with T4 stage, surgery followed by postoperative radiotherapy continues to be the treatment of choice.¹⁵ Dysphonia is a symptom common to a myriad of conditions. It is important to recognize that patients with head and neck cancer may present with hoarseness of voice and a failure to evaluate them, may lead to a delay in cancer diagnosis, resulting in higher staging, requiring a more aggressive treatment, and reduced survival chances.¹⁶ The primary goals of treatment for all the above mentioned conditions are not only surgically removing the lesion and further treatment based on the pathology but also improving the vocal quality and strength with a proper speech therapy.

Conclusion

In our study we concluded that the most common lesion causing hoarseness of voice includes the vocal cord

polyps. The majority of the patients were of the male gender and belonged to the age group of 31-40 years. Chronic vocal abuse and smoking were the risk factors noted in our study. The benign lesions included vocal cord polyps, cyst, nodules, keratosis, paillomas and some rare conditions like Fungal Laryngitis. These conditions were managed by surgical excision with the aid of endoscope or microscope in toto followed by necessary postoperative medications. The malignant lesions on the other hand, were managed according to the staging of the tumour. Vocal and voice hygiene before and after the surgery is an important aspect of the management. Thus our study throws light on the various features of the laryngeal causes for hoarseness of voice and their management in our institute.

References

1. Baitha, S., Raizada, R. M., Singh, A. K. K., Puttewar, M. P., & Chaturvedi, V. N. (2002). Clinical profile of hoarseness of voice. *Indian Journal of Otolaryngology and Head and Neck Surgery*, 54(1), 14–18. <https://doi.org/10.1007/bf02910998>
2. Pal, K. S., Kaushal, A. K., Nagpure, P. S., & Agarwal, G. (2014). Etiopathological study of 100 patients of hoarseness of voice: In a rural based hospital. *Indian Journal of Otolaryngology and Head and Neck Surgery: Official Publication of the Association of Otolaryngologists of India*, 66(1), 40–45. <https://doi.org/10.1007/s12070-013-0660-8>
3. Singhal, P., Bhandari, A., Chouhan, M., Sharma, M. P., & Sharma, S. (2009). Benign tumors of the larynx: a clinical study of 50 cases. *Indian Journal of Otolaryngology and Head & Neck Surgery*, 61(S1), 26–30. <https://doi.org/10.1007/s12070-009-0013-9>
4. Kim, J.-E. (2010). The hoarse patient: Asking the right questions. *The Permanente Journal*, 14(1), 51. <https://doi.org/10.7812/tpp/09-091>
5. Nikolaos S Mastronikolis, Theodoros A Papadas et al, Head and neck: Laryngeal tumors: an overview https://www.researchgate.net/publication/273558154_Head_and_neck_Laryngeal_tumors_an_overview
6. Baitha, S., Raizada, R. M., Singh, A. K. K., Puttewar, M. P., & Chaturvedi, V. N. (2004). Predisposing factors and aetiology of Hoarseness of voice. *Indian Journal of Otolaryngology and Head and Neck Surgery*, 56(3), 186–190. <https://doi.org/10.1007/bf02974347>
7. Feierabend, R. H., & Shahram, M. N. (2009). Hoarseness in adults. *American Family Physician*, 80(4). <https://pubmed.ncbi.nlm.nih.gov/19678604/>
8. Rubin, A. D., & Sataloff, R. T. (2007). Vocal fold paresis and paralysis. *Otolaryngologic Clinics of North America*, 40(5), 1109–1131. <https://doi.org/10.1016/j.otc.2007.05.012>
9. Agrawal, A., Qureshi, S., Kumar, A., Jadia, S., Ahlawat, B., & Prasad, S. (2016). Differential diagnosis of hoarseness of voice in the present scenario: a clinicopathological study. *Indian Journal of Scientific Research*, 179+. <https://go.gale.com/ps/i.do?id=GALE%7CA469757269&sid=googleScholar&v=2.1&it=r&linkaccess=abs&issn=09762876&p=AONE&sw=w&userGroupName=anon%7E2ade7792&aty=open-web-entry>
10. Minutha, & Associate Professor, Department of ENT, Vydehi Medical College and Research Centre, Bangalore, Karnataka, INDIA. (2020). Benign lesions of the vocal cords - An analysis of fifty cases. *MedPulse International Journal of*

- ENT, 16(3), 33–37.
<https://doi.org/10.26611/10161633>
11. Bhadesia, B., Sorathiya, R., Joshi, H., Desai, N., & Hirani, N. (2020). A descriptive study of benign vocal cord lesions. *International Journal of Otorhinolaryngology and Head and Neck Surgery*, 6(3), 478.
<https://doi.org/10.18203/issn.2454-5929.ijohns20200516>
12. Reiter, R., Hoffmann, T. K., Pickhard, A., & Brosch, S. (2015). Hoarseness. *Deutsches Arzteblatt International*, 112(19).
<https://doi.org/10.3238/arztebl.2015.0329>
13. Nerurkar, N. K., Agrawal, D., & Krishnan, R. (2022). A four year retrospective study of the pattern of fungal laryngitis in a tertiary voice care centre. *Indian Journal of Otolaryngology and Head and Neck Surgery: Official Publication of the Association of Otolaryngologists of India*, 74(4), 463–468. <https://doi.org/10.1007/s12070-021-02832-1>
14. Igissin, N., Zatonskikh, V., Telmanova, Z., Tulebaev, R., & Moore, M. (2023). Laryngeal cancer: Epidemiology, etiology, and prevention: A narrative review. *Iranian Journal of Public Health*, 52(11), 2248.
<https://doi.org/10.18502/ijph.v52i11.14025>
15. Kannan, R., & Pradhan, S. A. (2010). Treatment decision in the management of laryngeal cancer: An overview. *Otorhinolaryngology Clinics - An International Journal*, 2(3), 191–194.
<https://doi.org/10.5005/jp-journals-10003-1035>
16. Stachler, R. J., Francis, D. O., Schwartz, S. R., Damask, C. C., Digoy, G. P., Krouse, H. J., McCoy, S. J., Ouellette, D. R., Patel, R. R., Reavis, C. (charlie) W., Smith, L. J., Smith, M., Strode, S. W., Woo, P., & Nnacheta, L. C. (2018). Clinical practice guideline: Hoarseness (dysphonia) (update). *Otolaryngology--Head and Neck Surgery: Official Journal of American Academy of Otolaryngology-Head and Neck Surgery*, 158(S1).
<https://doi.org/10.1177/0194599817751030>