

A Preventable Cause of Hypotonia in Infants: Case Report of Two Infants with Vitamin B12 Deficiency

²M. Akhrif, ¹S.Saghir, ¹M. Kmari, ¹A. Ourrai, ¹A. Hassani, ¹R. Abilkassem, ¹A. Agadr

¹Department of Pediatric, Mohamed V Military Training Hospital, Rabat, Morocco.

²Children's hospital of Rabat, CHIS. MOROCCO

Corresponding Author: M. Akhrif, Children's hospital of Rabat, CHIS. MOROCCO

Type of Publication: Case Report

Conflicts of Interest: Nil

Abstract

Innate deficits in the metabolism or transport of vitamin B12 are exceptional. The main cause of vitamin B12 deficiency in infants is secondary to maternal deficiency. Maternal deficiency can have a vegan diet, low socio-economic level (developing countries) and a high level of development with a poor diet) or digestive pathologies responsible for a lack of absorption. The clinical signs are not very specific (developmental delay, pallor, hypotonia, vomiting and diarrhoea), which explains the frequent delay in diagnosis. The pathophysiology of the neurological damage, which is still uncertain, is thought to be secondary to a defect in myelination with altered nerve conduction and cortical atrophy. The aim of this work is to underline the importance of raising awareness of vitamin B12 deficiency in order to avoid its profound neurological repercussions, especially as substitution treatment allows an improvement or a reversibility of the neurological damage and raises the question of the possibility of screening newborns.

Materials And Methods: We report the case of two infants aged 6 months and 10 months with hypotonia and psychomotor regression from an early age, whose biological examination revealed pancytopenia with a collapsed vitamin B12 level in both infants and both mothers.

Keywords: cerebral atrophy; developmental regression; hypotonic infant; vitamin B12 deficiency.

Introduction

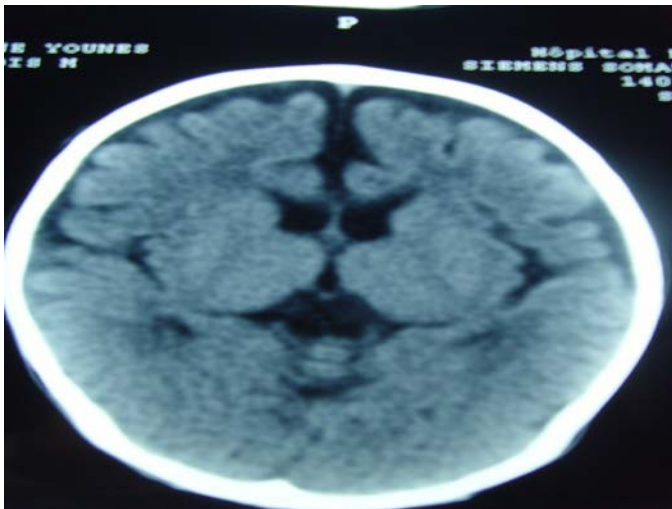
Vitamin B12 is one of the essential vitamins that affect the different systems in the organism, including the central nervous system. It has an active role in the metabolism of the nervous system, even though its exact role in pathological conditions is not entirely clear.[1]. Vitamin B12 deficiency is one of the avoidable causes of growth retardation and developmental abnormalities in infants. Vitamin B12 deficiency is more frequent in vegan-fed or malnourished mothers, especially in developing countries. [2]. Nutritional B12 deficiency is rare in children with non-specific symptoms, such as growth retardation, vomiting, anorexia and neurological manifestations with or without hematological disorders. [1].

Cases Reports

Case N1: Infant aged 6 months who presents since the age of 2 months an alteration of the general state, hypotonia, psychomotor regression, apathy, indifference to entourage and a slowing down of growth, the infant is under exclusive breastfeeding. Clinical examination finds hypotrophy with obvious staturponderal growth retardation. Weight 5200g (-3DS), height 59 cm (-3DS) and a PC: 41 cm (-1DS), intense pallor, poor contact, weak cry, axial hypotonia with slight peripheral hypertonia. Biological examinations showed pancytopenia

with a hemoglobin level at 6.5 g/dl and mean globular volume at 91 fl, reticulocyte level at 65000. White blood cell level at 6200 including 600 neutrophilic polynuclear cells and platelet level at 110000. The Medullogram showed a very rich marrow with maturation disorders. The Vitamin dosage was B12: 45 pg/ml collapsed. folate: 12, 3 ng/ml (3-19) normal. Homocysteine: 136 micromol/l (3.60-21.7). Chromatography of amino acids in blood and urine showed homocysteinuria. Brain CT scan revealed diffuse brain atrophy.

The search for an autoimmune disease associated with hypothyroidism in the mother led to the diagnosis of Biermer's disease. Vitamin B12 levels collapsed to 87.55 pg/ml and folate levels to 12.74 ng/ml, intrinsic antifactor antibody negative and parietal anticellule positive.



A sagittal section of cerebral CT scan of N1 cases: showing diffuse cerebral atrophy

Case N2: Infant aged 10 months who presents since the age of 4 months an alteration of the general state, hypotonia, a delay of psychomotor acquisitions, under exclusive breastfeeding of a vegetarian mother. The clinical examination found an intense pallor, an axial and peripheral hypotonia.

Biological examinations revealed pancytopenia with a hemoglobin level of 6 g/dl and a myelin globular

volume of 75 fl, a reticulocyte level of 55000. White blood cell count of 6200 of which 5500 were neutrophilic polynuclear cells and a platelet level of 2600000. Medullogram: very rich marrow with maturation disorders. The Vitamin B12 dosage: 35 pg/ml collapsed. The Folate dosage: 15, 3 ng/ml (3-19) normal. Brain CT scan revealed diffuse cortical atrophy.

The vitamin B12 dosage in the mother was collapsed at 107.55 pg/ml and the folate dosage at 12.74 ng/ml.

Treatment with vitamin B12 (Hydroxycobalamin) was started with an injection of 1 mg daily in IM for one week and then a weekly injection for one month and then monthly in both patients, with good clinical biological improvement and normalisation of vitamin B12 levels.

Discussion

B12 is a water-soluble vitamin that plays a role in the fundamental in our organism: works as an essential co-factor for enzymes, methionine synthetase (Catalyses the methylation of homocysteine to methionine) and the enzyme methylmalonyl-CoA mutant reductase (catalyses the conversion of methylmalonyl CoA into succinyl CoA).[3]. It is involved in haematopoiesis (anti-megaloblastic vitamin) and in neurological development (myelination) explaining the manifestations of clinical symptoms of vitamin B12 deficiency. In the newborn, the vitamin B12 reserve is built up in the antenatal period by transplacental passage.[4]. It is necessary to note that Vitamin B12 deficiency (<148 pmol/L) is a critical public health challenge around the world. [5]. Innate deficiencies in vitamin metabolism or transport of B12 are exceptional. The main cause of the deficit in vitamin B12 in infants is secondary to a deficiency maternal. This may be due to a vegetative diet. low socio-economic level or digestive pathologies responsible for a lack of absorption (infection with *Helicobacter pylori*, Biermer disease, disease celiac or

Crohn's disease, taking a pump inhibitor to proton).[6]. B12 is contained in animal products, not of plant origin, except if they are enriched. The vegetarian population has restricted sources of B12. Legumes have few in quantity and with low absorption. Even though vegans are at higher risk, those who eat less meat or fish once a week are equally at risk of B12 deficiency. [7]. Children of B12-deficient mothers can be born with a disability or manifest it later, if receive exclusive breastfeeding. Adequate intake and absorption of B12 during pregnancy and breastfeeding are the most relevant protective factors than the state of maternal deposits. [3]. B12 deficiency manifests itself in organs with elevated cell turnover, such as the bone marrow, which regulates erythropoiesis, and the nervous system, in which it affects axon repair and the synthesis of myelin and neurotransmitters, myelopathy, neuropathy, neuropsychiatric disorders and optic atrophy In children with congenital deficiency, damage to the central nervous system (CNS) is characterised by loss of white matter with delayed myelination[8]. The clinic varies from apathy and refusal of food to developmental regression, neuropathy with motor impairment and seizures.[9]. Measurement of vitamin B12 levels can assist in the diagnosis of vitamin B12 deficiency. Homocysteine and methylmalonic acid levels also are elevated in B12 deficiency. Diagnosis of vitamin B12 deficiency should not rely on an abnormal hemoglobin level, hematocrit level, especially in mild cases. [1]. Neurological signs may usually be expected in infants who are exclusively breastfed and who receive inadequate amounts of vitamin B12. Hypotonia and neurodevelopmental delay are the most commonly reported signs in infants. [10]. It is important to stress that vitamin B12 deficiency must be integrated into the diagnostic algorithm when faced with neurological images of unknown etiology. The increase in the number of cases may be related to the popularity of vegan diets. [3]. The

mechanisms underlying movement disorders secondary to B12 deficiency are not clear, it is thought that increased glycine acts as a stimulator on the cerebral cortex and has an inhibitory effect on the spinal cord. [11].

Although B12 deficiency is known to have neurological effects, there are few cases of neuroimaging in infants in the literature.[11]. in a study realised by Codazzi et al, reported diffuse cortical and subcortical atrophy without focal lesions or myelination disorder using MRI in a 10-month-old boy. In another case report of an infant aged 6 months with developmental regression, computed tomography demonstrated diffuse cerebral atrophy . [11]. In another study realised by Taskesen et al, reported that thinning of the corpus callosum was detected in six (40%) patients, cortical atrophy in five (33.3%), ventricular dilatation in three (20%), large Sylvian fissures in five (33.3%), hydrocephalus in three (20%), asymmetric large lateral ventricles in two (13.3%) and retardation in myelination in two (13.3%) patients, and four infants had normal MRI findings, respectively.[12]. Neurological involvement may exist without anaemia; anaemia is not essential for a suspected diagnosis.[3]. There are studies which have shown that haematological disorders are associated with neurological manifestations, this is the case of the study carried out by Acıpayam C et al which revealed that Fifty-seven percent of our patients had leukopenia, 67% had neutropenia, 48% had pancytopenia and 62% had thrombocytopenia.

The case of our two infants joins the studies published in the literature which have shown that vitamin B12 deficiency can associate pancytopenia with significant neurological disorders, and that the deficiency in infants under exclusive breastfeeding is closely linked to maternal deficiency.

Treatment consists of the administration of B12; intramuscular cyanocobalamin is started at a rate of 1

mg/day for one to two weeks, depending on the severity, and then, if there is clinical and laboratory improvement, it is continued with weekly or monthly parenteral or oral doses on a daily basis. [13]. Vitamin B12 supplementation normalizes the hematological and metabolic disturbances, but early treatment is crucial to prevent neurological sequelae such as learning or behavioural problems, secondary epilepsy or mental retardation. [5].

Conclusion

In recent years, the percentage of children born to vegan mothers has increased considerably due to the popularity of these diets. B12 deficiency is one of the most serious complications of children born to women who adopt vegetarianism without supervision. It is a challenge for the paediatrician and obstetrician to observe family feeding and provide pre-conception counselling to prevent deficiencies of micronutrients essential for mature development. The paediatrician should suspect B12 deficiency in the face of unexplained neurological impairment or the development of megaloblastic anaemia or pancytopenia. The importance lies in the fact that an early investigation and correction improves the neurological prognosis.

References

1. Serin HM, Arslan EA. Neurological Symptoms Of Vitamin B12 Deficiency: Analysis Of Pediatric Patients. *Acta Clin Croat.* 2019 Jun;58(2):295-302. Doi: 10.20471/Acc.2019.58.02.13. PMID: 31819326; PMCID: PMC6884369.
2. Black MM. Effects of vitamin B12 and folate deficiency on brain development in children. *Food Nutr. Bull.* 2008; 29 (2 Suppl.): 126–3
3. Aguirre JA, Donato ML, Buscio M, Ceballos V, et al. Compromiso neurológico grave por déficit de vitamina B12 en lactantes hijos de madres veganas y vegetarianas. *Arch Argent Pediatr* 2019;117(4):e420-e424.
4. Caltagirone J, Dupont A, Afanetti M, Gondon E, Dupont D. Régression psychomotrice par carence en vitamine B₁₂ [Psychomotor regression due to vitamin B₁₂ deficiency]. *Arch Pediatr.* 2016 Dec;23(12):1270-1272. French. doi: 10.1016/j.arcped.2016.08.015. Epub 2016 Oct 12. PMID: 27743764.
5. Bousselamti A, El Hasbaoui B, Echahdi H, Krouile Y. Psychomotor regression due to vitamin B12 deficiency. *Pan Afr Med J.* 2018 Jun 20;30:152. doi: 10.11604/pamj.2018.30.152.12046. PMID: 30374398; PMCID: PMC6201603.
6. Demir N, Koc A, Ustyol L, et al. Clinical and neurological findings of severe vitamin B12 deficiency in infancy and importance of early diagnosis and treatment. *J Paediatr Child Health* 2013;49: 820–4
7. Bravo JP, Ibarra CJ, Paredes MM. Compromiso neurológico y hematológico por déficit de vitamina b12 en lactante hijo de madre vegetariana: Caso Clínico. *Rev Chil Pediatr.* 2014; 85(3):337-43.
8. Serin Hm, Kara Ao, Oğuz B. West syndrome due to vitamin B12 deficiency. *Turk Pediatri Ars.* 2015; 50(4):251-3.
9. Racioppi F, Villamayor G, Serrano N. Manifestaciones Neurológicas del Déficit de vitamina B12 en pediatría. *Med Infant.* 2017; 24(1):27-30.
10. Serin HM, Arslan EA. Neurological symptoms of vitamin B12 deficiency: analysis of pediatric patients. *Acta Clin Croat.* 2019 Jun;58(2):295-302. doi: 10.20471/acc.2019.58.02.13. PMID: 31819326; PMCID: PMC6884369
11. Acıpayam C, Güneş H, Güngör O, İpek S, Sarışık N, Demir NŞ. Cerebral atrophy in 21 hypotonic infants with severe vitamin B12 deficiency. *J Paediatr Child*

- Health. 2020 May;56(5):751-756. doi:
10.1111/jpc.14733. Epub 2019 Dec 23. PMID:
31868292.
12. Taskesen M, Yaramis A, Pirinccioglu AG, Ekici F. Cranial magnetic resonance imaging findings of nutritional vitamin B12 deficiency in 15 hypotonic infants. *Eur. J. Paediatr. Neurol.* 2012; 16: 266–70
13. Guez S, Chiarelli G, Menni F, Salera S, et al. Severe vitamin B12 deficiency in an exclusively breastfed 5-month-old Italian infant born to a mother receiving multivitamin supplementation during pregnancy. *BMC Pediatr.* 2012; 12:85

How to citation this article: M. Akhrif, S.Saghir, M. Kmari, A. Ourrai, A. Hassani, R. Abilkassem, A. Agadr, “A Preventable Cause of Hypotonia In Infants: Case Report of Two Infants With Vitamin B12 Deficiency”, *IJMACR- September - October - 2020, Vol – 3, Issue -5, P. No. 198 –202.*

Copyright: © 2020, M. Akhrif, et al. This is an open access journal and article distributed under the terms of the creative commons attribution noncommercial License 4.0. Which allows others to remix, tweak, and build upon the work non-commercially, as long as appropriate credit is given and the new creations are licensed under the identical terms.
