

The Safety and Efficacy of A Novel Prechopper for In The Bag Phacofragmentation in Manual Small Incision Cataract Surgery Vs Conventional Manual Small Incision Cataract Surgery – A Quasi Experimental Study At A Tertiary Care Centre

¹Dr Sohel Irfan Mohd Khan, Professor and HOD, Department of Ophthalmology, Government Medical College, Akola, Maharashtra

²Dr Shruti Shirang Kavimandan, Junior Resident, Department of Ophthalmology, Dr Shankarrao Chavan Government Medical College, Nanded, Maharashtra

³Dr Atul Sheshrao Raut, Professor and HOD, Department of Ophthalmology, Dr Shankarrao Chavan Government Medical College, Nanded, Maharashtra

Corresponding Author: Dr Atul Sheshrao Raut, Professor and HOD, Department of Ophthalmology, Dr Shankarrao Chavan Government Medical College, Nanded, Maharashtra

How to citation this article: Dr Sohel Irfan Mohd Khan, Dr Shruti Shirang Kavimandan, Dr Atul Sheshrao Raut, “The Safety and Efficacy of A Novel Prechopper for In The Bag Phacofragmentation in Manual Small Incision Cataract Surgery Vs Conventional Manual Small Incision Cataract Surgery – A Quasi Experimental Study At A Tertiary Care Centre”, IJMACR – April – 2026, Volume – 9, Issue – 2, P. No. 57 – 66.

Open Access Article: © 2026 Dr Atul Sheshrao Raut, et al. This is an open access journal and article distributed under the terms of the creative common’s attribution license (<http://creativecommons.org/licenses/by/4.0>). Which allows others to remix, tweak, and build upon the work non-commercially, as long as appropriate credit is given and the new creations are licensed under the identical terms.

Type of Publication: Original Research Article

Conflicts of Interest: Nil

Abstract

Background: Manual small incision cataract surgery (MSICS) remains the procedure of choice in high-volume cataract programs across the developing world due to its low cost, short learning curve, and relative independence from sophisticated instrumentation^{1,2}. However, nuclear management presents ongoing challenges including large scleral incisions, zonular stress, posterior capsule rupture and endothelial damage³.

Purpose: This study evaluates the clinical performance, safety profile, and operative efficacy of a novel sickle

shaped prechopper (Dr. Sohel Khan’s novel prechopper) for in-the-bag nuclear fragmentation in MSICS compared with conventional MSICS without a dedicated prechopping instrument.

Methods: A prospective comparative analysis was conducted across a tertiary eye care centre. Outcome measures included nuclear fragmentation efficacy, incidence of complications, postoperative corneal edema, induced astigmatism and postoperative visual acuity.

Results: The novel prechopper demonstrated statistically significant advantages in reducing the

incision size, early recovery, lowering cumulative surgically induced stress to intraocular structures, lowering the postoperative surgically induced corneal astigmatism and lowering the postoperative corneal edema rates.

Keywords: Cataract, Carmona Technique, MSICS, Prechoppers

Introduction

Cataract remains the single largest cause of reversible blindness worldwide, accounting for over half of all blindness cases in low- and middle-income countries ⁴. Among the surgical approaches developed to address this burden, manual small incision cataract surgery (MSICS) has established itself as the technique of choice in high-volume, resource-limited settings ^{1,2}. Its cost profile, minimal infrastructure requirements, and visual outcomes that closely approximate those of phacoemulsification make it particularly suited to large-scale blindness control programs.

The key technical challenge in MSICS is extracting the nucleus safely through a scleral tunnel without damaging the endothelium, without imposing damaging stress on the zonular apparatus or posterior capsule and without inducing much astigmatism ^{3,5}. Conventional approaches rely on techniques such as the fish-hook, wire vectis, or irrigating vectis to deliver the nucleus as a whole after positioning an instrument posterior to it. While widely practised, these methods warrant the delivery of the nucleus first into the anterior chamber thereby risking the integrity of the endothelium ⁶, also they exert considerable mechanical force on the capsular bag, and their complication profile increases substantially with denser nuclei.

Newer anterior chamber fragmentation techniques such as the bisector, trisector, the Keener snare technique or

the Carmona technique are performed in the vicinity of the endothelium jeopardising its integrity ^{7,8}.

Additionally, larger nuclei necessitate larger incisions, increasing postoperative astigmatism ⁵.

The concept of in the bag nuclear fragmentation using this novel device addresses this problem by dividing the nucleus into smaller, more manageable segments before extraction. There are plethora of prechoppers in the market but each carries their own limitations: some of them carry out this fragmentation in the AC jeopardizing the endothelial integrity and defeats the purpose of obtaining a pristine clear cornea on day 1 of surgery, some require wider tunnel dimensions, others have limited efficacy in hard nuclei, and several impose a steep learning curve without providing reliable posterior capsule protection during the chopping manoeuvre ^{9,10}.

This novel instrument overcomes these collective problems because of its elegant and sleek design with a sharp cutting edge. Our novel prechopper has an advantage over these pre-existing ones as it divides the nucleus in the capsular bag itself, far away from the endothelium, is affordable and comparatively easier to master with very few complications. This is due to the fact that using this prechopper the forces applied for chopping the nucleus are in a horizontal direction towards each other, exerting much less force on the zonules.

The present study offers the first prospective, randomized evaluation of this instrument against conventional MSICS, examining safety and efficacy with reference to incision size, postoperative astigmatism, visual outcome, intra-operative and postoperative complications.

Design and Dynamics of Prechopper

An ergonomically designed prechopper features a sleek curved blade integrated with its shaft. The blade comprises an inner cutting edge, outer blunt edge, and pointed tip, with tip thickness typically 0.2–0.5 mm and shaft width 0.75–1 mm. The blade–shaft angle ranges from -100° to 110° . This technique enables efficient engagement of both soft and dense nuclei due to its sharp edges (0.5–0.7mm) and pointed tip, while exerting minimal zonular stress. Hard or mobile nuclei may generate torsion, requiring slow, controlled movements for safe nuclear division. Care is needed when hooking the equator with a horizontal chopper to avoid zonular dialysis.¹¹

Materials and Methodology

A prospective randomised trial was carried out at Government Medical College and Hospital, Nanded, spanning over 18 months, enrolling 100 eyes from 100 individual patients. Prior to enrollment, written informed consent was obtained from all participants, and the institutional ethics committee granted approval for the study. Eligible participants fell within the 50–75 year age bracket and presented with senile cataract accompanied by nuclear sclerosis graded 2 or 3. Patients were excluded if they had any co-existing ocular condition capable of influencing postoperative visual outcomes, including posterior segment pathology, changes secondary to uveitis, corneal opacification or degeneration, inadequate pupillary dilation, shallow anterior chamber, lens subluxation or dislocation, developmental or traumatic cataract, or a prior surgical history in the operative eye.

A comprehensive preoperative workup was performed for every participant, encompassing best-corrected visual acuity (BCVA), intraocular pressure (IOP)

measurement, keratometry, thorough slit lamp examination to look for endothelial health and a thorough systemic evaluation. IOL power calculation was standardised across all patients using a single A-scan machine and the SRK-T formula.

Participants were randomly allocated into two equal groups of 50 patients each. Group I was subjected to Manual Small Incision Cataract Surgery (MSICS) utilising the novel prechopper, while Group II underwent conventional MSICS. A single experienced surgeon performed all operative procedures to ensure consistency.

Surgical Technique

Pupillary dilation was achieved through instillation of 0.8% tropicamide and 5% phenylephrine eye drops into the conjunctival fornix. Peribulbar anaesthesia was administered using a combination of 3 ml of 2% lignocaine, 2 ml of 0.5% bupivacaine, and hyaluronidase enzyme at 15 units/ml. The conjunctiva and Tenon's capsule were dissected from the limbus between the 10 o'clock and 2 o'clock positions, extending approximately 4 mm posterior to the limbus in group II, whereas for group I a limited peritomy of around 2 clock hours was performed. In group I, a scleral incision of 2.5 mm length measured with an incision caliper with 1 mm back cut on either side was fashioned using an 11 no. blade or 15 degree blade [sideport], and a sclero-corneal tunnel was subsequently dissected for 1.5 mm in the clear cornea with extension on either side with 1mm pocket on either side with a crescent blade. While in group II a scleral incision of around 6–7 mm was made, according to the nuclear grading followed by sclero-corneal tunnel construction. Two side-port incisions, each measuring 1.2 mm, were placed at the 10 o'clock and 2 o'clock positions, and the anterior chamber was

stabilised with an air bubble. Entry into the anterior chamber was made using a 2.8 mm keratome, with appropriate extension of the incision. Trypan blue was applied to stain the anterior lens capsule, after which the dye was irrigated out through the side port and AC maintainer was fixed through which an assistant was injecting viscoelastic material generously to maintain AC depth at all times of surgery. A continuous curvilinear capsulorhexis (CCC) measuring 5.5–6.0 mm was fashioned using Haldipurkar forceps. Hydrodissection was performed and free nuclear rotation was confirmed. Viscoelastic was then injected generously to maintain the anterior chamber depth.

At this stage, the two groups diverged in technique. In Group II, the nucleus was extracted using conventional viscoexpression. In Group I, a Chang's horizontal chopper or Akahoshi ball sustainer was introduced through the 2 o'clock side port and directed beneath the anterior capsule into the capsular bag to engage the nuclear equator. The novel prechopper was then introduced through the main incision, with its sharp tip advanced deeply into the endonucleus just anterior to the capsulorhexis margin and driven into the nuclear core, while the opposing instrument provided counter-support at the equator. The two instruments were brought toward each other to achieve a clean pre-chop. The nucleus was then rotated and subdivided into smaller, manageable fragments. Under a generous viscoelastic cover, the nuclear fragments were expressed using a micro-wire vectis. Residual cortical matter was aspirated via Simcoe cannula, following which a foldable intraocular lens was implanted into the capsular bag under viscoelastic protection. The viscoelastic was then removed, side ports were hydrated, and an air bubble was placed in the anterior chamber. A subconjunctival injection of

gentamicin combined with dexamethasone was administered, and the eye was dressed with a sterile eye pad.

Outcome Measures

Incision size, visual acuity, surgically induced astigmatism, and corneal oedema were evaluated and compared between the two groups at postoperative day (POD) 1, 7, 15, and 40. Visual acuity was recorded using a Snellen chart. Surgically induced astigmatism was derived from keratometry readings obtained on the same instrument used preoperatively. Corneal oedema was assessed at the slit lamp and graded on a five-point scale as per the BJO grading : Grade 0 (None) — clear cornea with no oedema; Grade 1 (Mild) — faint haze with minimal corneal thickening or subtle Descemet's folds; Grade 2 (Moderate) — evident stromal oedema with visible Descemet's folds and/or measurable corneal thickening; Grade 3 (Severe) — marked corneal haze, dense stromal folds, and/or localised microcystic changes; Grade 4 (Very Severe) — diffuse bullous keratopathy with substantial thickening and significantly compromised anterior segment view.

Collected data was entered in MS Excel. Quantitative data expressed in mean and standard deviation. Non normal data expressed in Median and Inter quartile range. Qualitative data expressed in frequency and percentage. Use appropriate test of significance (statistical test). If data do not follow normal distribution, use Mann Whitney U test. If $p < 0.05$ statistically significant, otherwise non – significant.

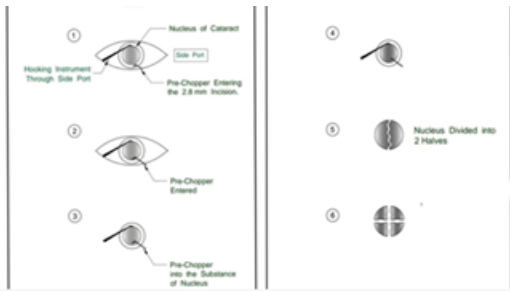


Figure 1:

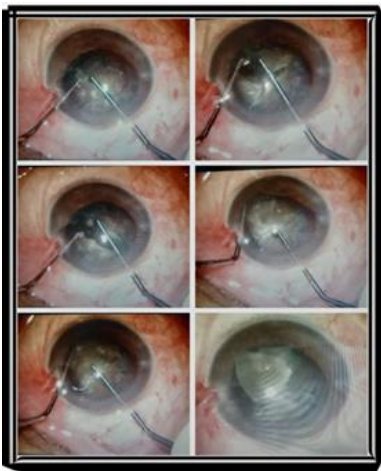


Figure 2:

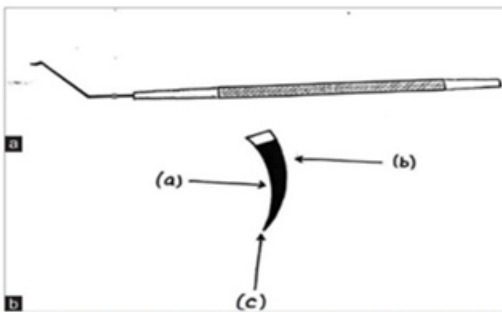


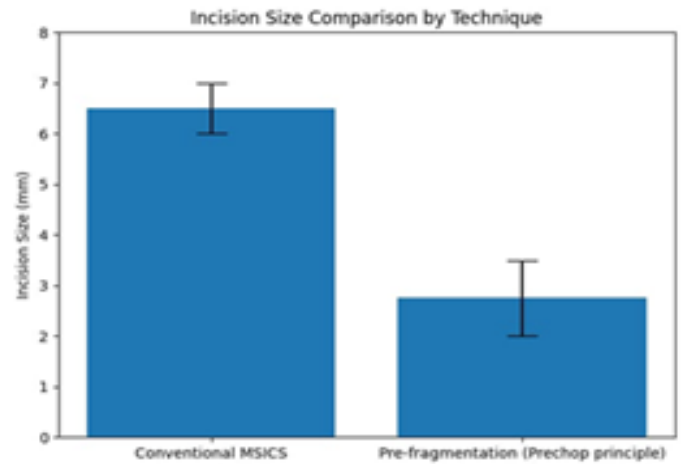
Figure 3: (a) and (b) Design of the prechopper, (a) Inner cutting edge, (b) Outer blunt edge, (c) Pointed tip



Figure 4: Dr. Sohel Khan's prechopper with a sharp pointed tip and cutting edge

Results

Incision Size



The use of the prechopper technique demonstrated a notable reduction in the incision size required for nuclear delivery compared to conventional Manual Small Incision Cataract Surgery (MSICS). Nuclear fragments of equivalent grading could be successfully extracted through an incision as small as 2 mm, whereas the conventional approach necessitated a significantly larger incision of approximately 6–7 mm for the same nuclear density. This substantial reduction in incision size was associated with clinically meaningful benefits, including accelerated postoperative recovery, earlier visual rehabilitation, and a significant decrease in surgically induced astigmatism.

Visual Acuity

Table 1:

Visual Acuity (With Prechopper)	POD 1	POD 7	POD 15	POD 30	VISUAL ACUITY (Conventional)	POD 1	POD 7	POD 15	POD 30
6/6 – 6/12	25	33	40	47	6/6 – 6/12	18	27	37	45
6/18 - 6/36	18	17	10	3	6/18 - 6/36	24	23	13	5
6/60 – FC 4m	7	-	-	-	6/60 – FC 4m	8	-	-	-
FC 3m - PL	-	-	-	-	FC 3m - PL	-	-	-	-
Total	50	50	50	50	TOTAL	50	50	50	50

Visual recovery was faster and final acuity outcomes were superior in the prechopper group at all follow-ups. The patients in Group I achieved a faster recovery than those in group II, the gap being more pronounced at POD 1, suggesting less surgical trauma and faster corneal clearing.

Even though prechopper offers a faster visual rehabilitation, long term final outcomes are comparable between the 2 approaches.

The proportion of patients achieving best corrected visual acuity of 6/6 – 6/12 was higher in the prechopper group at all postoperative intervals; however, this difference was not stastically significant [p > 0.05].

Induced Astigmatism

Table 2:

Postop Surgically Induced Astigmatism In Dioptres (With Prechopper)	No of Patients	%	Postop Surgically Induced astigmatism In Dioptres (Conventional)	No of Patients	%
0D – 0.25D	15	30%	0D – 0.25D	-	-
0.25D – 0.50D	25	50%	0.25D – 0.50D	8	5%
0.50D – 0.75D	5	10%	0.50D – 0.75D	10	20%
0.75D – 1.00D	5	10%	0.75D – 1.00D	20	40%
1.00D – 1.25D	-	-	1.00D – 1.25D	15	30%
1.25D – 1.50D	-	-	1.25D – 1.50D	7	5%
TOTAL	50		Total	50	

Postoperative surgically induced astigmatism (SIA) was compared between two groups: MSICS with prechopper and conventional MSICS, each comprising 50 patients. In the prechopper group, the majority of patients exhibited lower degrees of astigmatism. This indicates that the prechopper technique is associated with minimal surgically induced astigmatism, with 80% of patients having SIA ≤ 0.50 D.

In contrast, the conventional MSICS group showed a tendency toward higher degrees of astigmatism.

The mean surgically induced astigmatism was significantly lower in the prechopper group (0.37 ± 0.24 D) compared to the conventional group (0.80 ± 0.30 D) (p < 0.001).

Overall, these findings suggest that MSICS with a prechopper results in significantly lower surgically

induced astigmatism compared to the conventional technique. Most patients in the prechopper group achieved astigmatism within the lower range (<0.50 D), whereas the conventional group showed a higher

distribution of moderate to higher astigmatism (≥ 0.75 D). This highlights the advantage of the prechopper technique in reducing postoperative refractive changes.

Corneal Edema

Table 3:

POD 1 Corneal Edema (With Prechopper)	No.	POD 1 Corneal Edema (Conventional)	No.
GRADE 0	43	GRADE 0	30
GRADE 1	4	GRADE 1	9
GRADE 2	3	GRADE 2	7
GRADE 3	0	GRADE 3	4
GRADE 4	0	GRADE 4	0

Despite the employment of copious viscoelastic agent during nuclear fragment delivery into anterior chamber, supplemented by continuous viscoelastic injection through an anterior chamber maintainer by a surgical assistant a subset of patients demonstrated clinically significant corneal oedema on the first postoperative day. This oedema however, showed a substantial resolution in the first week itself.

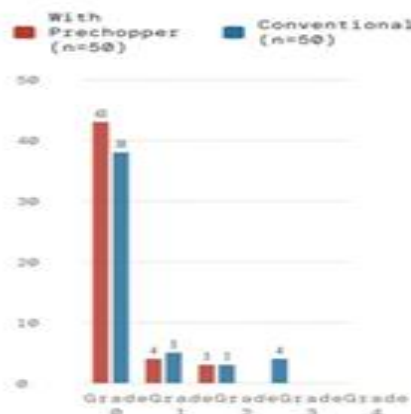
The mean corneal edema grade on postoperative day 1 was significantly lower in the prechopper group (0.20 ± 0.52) compared to the conventional group (0.90 ± 1.00) ($p = 0.002$).

Notably, the incidence and severity of corneal oedema were comparatively greater in conventional MSICS than with prechopper group as AC maintainer was continuously injecting viscoelastic, suggesting a potential endothelial protective advantage of the latter technique.

In the absence of specular microscopy, postoperative endothelial status could not be assessed by direct cell count analysis. Therefore, corneal oedema observed on slit lamp biomicroscopy was utilised as a surrogate marker for endothelial compromise, and it's severity was graded in accordance with the British Journal of Ophthalmology (BJO) grading system.

Corneal Edema at POD 1

PRECHOPPER VS. CONVENTIONAL - DISTRIBUTION BY GRADE



Notably, very few intraoperative complications including zonular dehiscence, Descemet's membrane detachment, or posterior capsule rupture were encountered during the use of this instrument.

Among the 50 patients operated, zonular dehiscence was observed in only 1 case and was managed by CTR implantation. No PCR was observed as prechopping was performed away from the posterior capsule due to the safety profile of the instrument, thus establishing a safety profile comparable to that of conventional Manual Small Incision Cataract Surgery (MSICS).

Discussion

Several prechop techniques, including that described by Akahoshi, have been reported in the literature; however, each is associated with specific limitations. In the present study, we describe a novel prechopping technique utilizing a specially designed prechopper, which is applicable across all grades of cataract, including cases with pseudoexfoliation, posterior polar cataract, and generalized zonular weakness.

The instrument is compatible with 2.2–2.8 mm corneo-scleral incisions and is characterized by a pointed tip and a sharp cutting edge, facilitating effective nuclear segmentation. Its sickle-shaped configuration enhances intraocular safety by minimizing the risk of posterior capsular injury.

The Akahoshi prechop technique, although well established, is associated with a steep learning curve and carries the risk of complications such as zonular dialysis and posterior capsular rupture. Furthermore, it may result in anterior chamber instability due to viscoelastic egress and is less effective in cases of dense nuclei^{9,10}.

Alternative techniques also present notable drawbacks.

The middle prechop technique, which employs two cystotomes, may exert excessive stress on the zonular apparatus and lacks precision¹²

In contrast, the technique described in this study avoids the application of downward force. Instead, both instruments are advanced toward the center in a controlled and coordinated manner, thereby minimizing zonular stress. The sharp tip and cutting edge of the prechopper allow for efficient engagement and division of both soft and hard nuclei.¹¹

The miLoop device, although effective for in-the-bag fragmentation, is a costly single-use instrument and is associated with a learning curve and a documented risk of posterior capsular rent¹³. Similarly, the reverse chopper technique involves blind intra-bag manipulation, rendering it technically challenging and operator-dependent.¹⁴

Femtosecond laser-assisted nuclear fragmentation requires high-cost equipment, which limits its utility in resource-constrained settings. Additionally, it may be associated with technical challenges in cases with small pupils, deep-set eyes, or dense cataracts, and carries a potential risk of inflammatory complications, including uveitis, elevated intraocular pressure, corneal edema, early posterior capsular opacification, and cystoid macular edema^{15,16}.

In summary, the technique described herein represents a cost-effective, reproducible, and versatile alternative for in-the-bag nuclear fragmentation, with applicability across a wide spectrum of cataract grades and clinical scenarios.

Conclusion

The novel sickle-shaped prechopper represents a safe, effective, and economical innovation in MSICS. It enables controlled in-the-bag nuclear fragmentation,

significantly reduces incision size and surgically induced astigmatism, and enhances early postoperative recovery, making it a coveted and extremely valuable tool in the armamentarium of a cataract surgeon operating in a high-volume and resource-limited settings.

References

1. Ruit S, Tabin G, Chang D, Bajracharya L, Kline DC, Richheimer W, et al. A prospective randomized clinical trial of phacoemulsification vs manual sutureless small-incision extracapsular cataract surgery in Nepal. *Am J Ophthalmol.* 2007;143(1):32–38.
2. Gogate PM, Kulkarni SR, Krishnaiah S, Deshpande RD, Joshi SA, Palimkar A, et al. Safety and efficacy of phacoemulsification compared with manual small-incision cataract surgery. *Indian J Ophthalmol.* 2005;53(4):249–254.
3. Venkatesh R, Tan CS, Sengupta S, Ravindran RD, Krishnan KT, Chang DF. Phacoemulsification versus manual small-incision cataract surgery for white cataract. *J Cataract Refract Surg.* 2010;36(11):1849–1854.
4. Flaxman SR, Bourne RRA, Resnikoff S, Ackland P, Braithwaite T, Cicinelli MV, et al. Global causes of blindness and distance vision impairment. *Lancet Glob Health.* 2017;5(12):e1221–e1234.
5. Hennig A, Johnson GJ, Evans JR, Minassian DC. Sutureless cataract surgery with nucleus extraction: outcome and complications. *Br J Ophthalmol.* 1999;83(5):561–565.
6. Blumenthal M, Moisseiev J. Sutureless extracapsular cataract extraction using the anterior chamber maintainer. *J Cataract Refract Surg.* 1987;13(2):204–206.
7. Keener JM. The snare technique for nucleus division. *J Cataract Refract Surg.* 1993;19(4):561–564.
8. Carmona C. Nucleus fragmentation techniques in MSICS. *Ophthalmic Surg Lasers Imaging.* 2000;31(6):480–485.
9. Akahoshi T. Prechop technique for phacoemulsification. *J Cataract Refract Surg.* 1998;24(6):715–717.
10. Berger A, Contin IN, Nicoletti G, Baltar Pazos PF, Baltar Pazos HS, Gomes JAP. Middle prechop: Fracturing the middle portion of the nucleus. *J Cataract Refract Surg.* 2012;38(4):564–567.
11. Khan SIM. Dr. Sohel Khan's prechopper and prechopping technique. *Indian J Ophthalmol.* 2024;72(9):1369–1371. doi:10.4103/IJO.IJO_2792_23
12. Berger A, Contin IN, Nicoletti G, Baltar Pazos PF, Baltar Pazos HS, Gomes JAP. Middle prechop: fracturing the middle portion of the nucleus. *J Cataract Refract Surg.* 2012 Apr;38(4):564–567. doi:10.1016/j.jcrs.2012.02.001.
13. Ianchulev T, Chang DF, Koo E, et al. Microinterventional endocapsular nucleus disassembly (miLoop). *J Cataract Refract Surg.* 2019;45(10):1427–1432.
14. Yang K, Song C, Li J, Zhang W, Liu Z, Zhao Y. Application of a prechop technique using a reverse chopper in small pupil cataract surgery. *BMC Ophthalmol.* 2020;20:392. doi:10.1186/s12886-020-01659-7. PMID: 33241038; PMCID: PMC7576071.
15. Nagy ZZ, Takacs AI, Filkorn T, Kránitz K. Complications of femtosecond laser-assisted cataract surgery. *J Cataract Refract Surg.* 2014;40(1):20–28.

16. Abell RG, Kerr NM, Vote BJ. Toward zero effective phacoemulsification time using femtosecond laser pretreatment. *Ophthalmology*. 2013;120(5):942–948.